

# SUPRASCAPULAR NEUROPATHY ASSOCIATED WITH MASSIVE ROTATOR CUFF TEARS: A RATIONALE FOR ARTHROSCOPIC ROTATOR CUFF REPAIR

JON J.P. WARNER, M.D., JOHN G. COSTOUIROS, M.D., MASON PORRAMATIKUL, M.D., DENNY T. LIE, F.R.C.S.

HARVARD SHOULDER SERVICE, DEPARTMENT OF ORTHOPAEDIC SURGERY, MASSACHUSETTS GENERAL HOSPITAL, BOSTON, MA

## INTRODUCTION

Massive rotator cuff tears may be present in patients with minimal pain and good function, or in patients with significant pain and disability.<sup>5,6,14,26</sup> In the latter case, arthroscopic repair, either partial or complete, has been demonstrated to improve function.<sup>3,11,20,21</sup> The mechanism of recovery is believed to be associated with an improved rotator cuff function due to at least partial healing of the posterior portion of the tendon repair.<sup>6-8,11,16,18,22</sup> However, retear after repair of a massive tear has been shown to be common.<sup>13,17</sup>

Recently, it has been suggested that a consequence of tendon tearing and retraction is traction on the suprascapular nerve (SSN) with the result being suprascapular nerve dysfunction (SSND) presenting as pain and weakness (Figs. 1A and

B).<sup>1,2</sup> The anatomy of the suprascapular nerve has been well described by others who have emphasized the relatively fixed position of the nerve as it passes beneath the transverse scapular ligament, thus making it especially prone to injury.<sup>4,23-25,27-29,31</sup> In addition, previous studies have demonstrated the limits of lateral advancement of the rotator cuff before placing these neurovascular structures at risk during operative repair.<sup>31</sup>

It has been suggested that improved pain and function despite radiographic evidence of a failed rotator cuff repair may be the result of complete or partial decompression of a tethered suprascapular nerve.<sup>1,2</sup> In a prospective series of eight consecutive patients with massive rotator cuff tears, Albritton and coworkers reported that all patients had evidence of suprascapular nerve dysfunction with severe limitation of active motion and pain.<sup>2</sup> Half of the patients elected for partial arthroscopic rotator cuff repair with significant improvement in function at an average sixteen month followup. Vad examined the prevalence of peripheral neurologic injuries in twenty-five patients with full-thickness tears of the rotator cuff associated with shoulder muscle atrophy. He noted a 28% prevalence of peripheral neuropathy, primarily involving the axillary and suprascapular nerves in patients with full-thickness rotator cuff tears.<sup>30</sup>

The purpose of our study was to test two hypotheses:

**Hypothesis #1:** SSND is not uncommonly associated with massive rotator cuff tears.

**Hypothesis #2:** Arthroscopic repair of massive rotator cuff tear in patients with SSND will result in improved pain and function which will correlate with recovery of SSND.

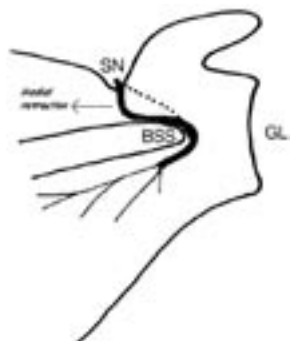


Figure 1A. Suprascapular nerve traction at the suprascapular notch with medial retraction of supraspinatus tendon (From Albritton et al. J Shoulder and Elbow. 12:497-500, 2003).

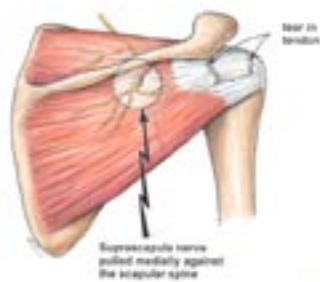


Figure 1B. Suprascapular nerve traction around the base of the spine of the scapula occurring with medial and inferior retraction of a torn infraspinatus tendon.

Dr. Warner is Chief, Partners Shoulder Service; Associate Professor of Orthopaedic Surgery, Harvard Medical School  
Dr. Costouros is a clinical fellow, Harvard Shoulder Service, Massachusetts General Hospital  
Dr. Porramatikul is a visiting surgeon on the Harvard Shoulder Service  
Dr. Lie is a visiting fellow on the Harvard Shoulder Service

Corresponding Author:

Jon J.P. WARNER, M.D.  
Harvard Shoulder Service  
Department of Orthopaedic Surgery  
Massachusetts General Hospital  
Yawkey Center for Outpatient Care  
55 Fruit Street, Suite 3200  
Boston, MA 02114  
E-mail: jwarner@partners.org  
Office: (617) 724-7300  
Fax: (617) 724-3846

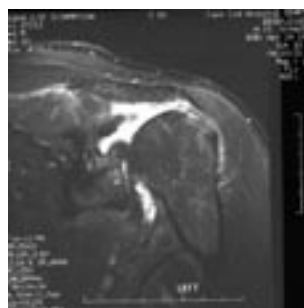


Figure 2A. Magnetic resonance imaging of a massive rotator cuff tear in the coronal plane. There is superior displacement of the humeral head and medial tendon retraction.

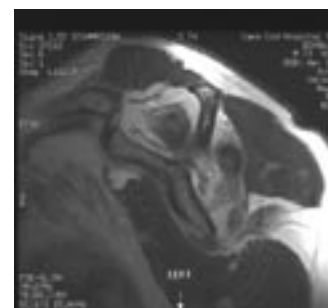

Figure 2B. Magnetic resonance imaging in the oblique sagittal plane demonstrates moderate-severe fatty replacement of both the supraspinatus and infraspinatus muscles.

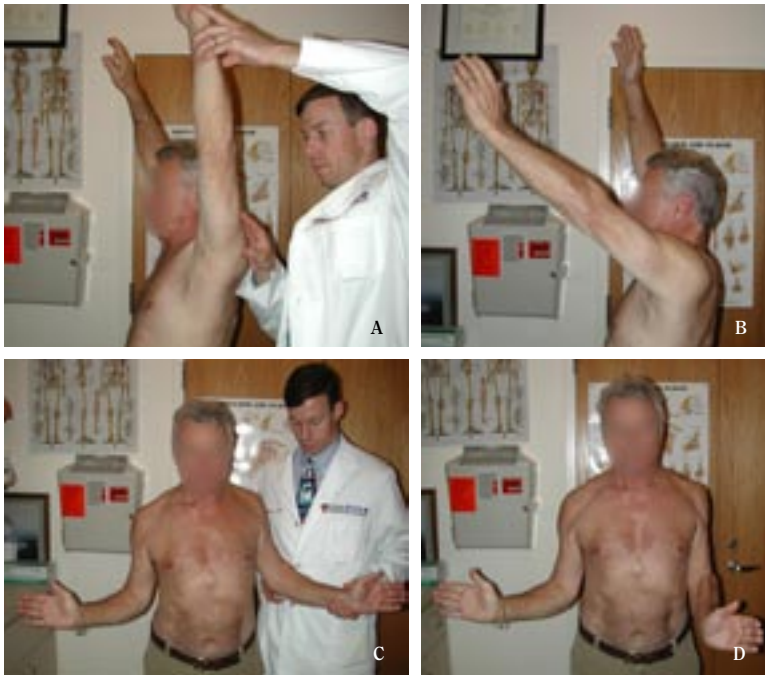

Figure 3A. Passive flexion in a patient (EB) with a massive rotator cuff tear.  
 Figure 3B. Active flexion in the same patient shows a lag between active and passive motion.  
 Figure 3C. Passive external rotation in patient (EB) with massive rotator cuff tear.  
 Figure 3D. Active external rotation in same patient with massive rotator cuff tear shows lag between active and passive external rotation.




Figure 4. Preoperative EMG and NCV study in patient with massive rotator cuff tear.

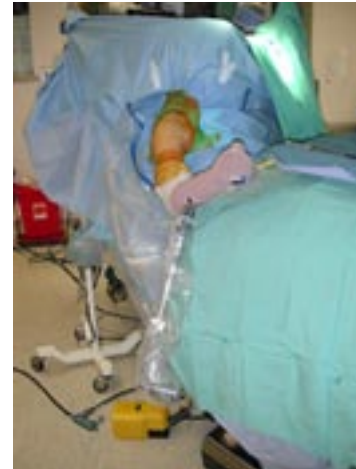

Figure 5. Beach-chair position for arthroscopic rotator cuff repair. (See text for explanation).

**Table 1. Patient demographic data.**

Patient	Age	M/F	SIDE	Mechanism of Injury	Pain
DC	68	M	R	Fell cross-country skiing	moderate
GL	60	M	L	Fell off of a ladder	severe
RB	41	M	R	Bench pressing/fall of bicycle	moderate
EB	73	M	L	Fell onto outstretched hand	moderate
KB	47	F	R	Fell while hiking	moderate
GG	55	M	L	Slipped and fell on ice	moderate

**METHODS**

**STUDY COHORT**

Over a thirteen-month period, twenty-six of two hundred sixteen patients with rotator cuff tears requiring surgery were identified to have massive tears in association with retraction and moderate to severe fatty muscle atrophy of the supraspinatus and infraspinatus (Figs. 2A and B).<sup>15</sup> All patients had pain as well as marked abduction and external rotation weakness (Figs. 3A-D). This group of patients was consistent in that all demonstrated a significant lag between passive and active flexion and external rotation, which has been noted as the hallmark of a massive postero-superior rotator cuff tear.<sup>19</sup>

Electrodiagnostic evaluation consisting of electromyography (EMG) and nerve conduction velocity (NCV) was performed on all twenty-six patients by one experienced neurologist blinded to clinical information about each patient.<sup>12</sup> This included motor and sensory nerve studies of radial, median, and ulnar nerves as well as motor studies of the suprascapular and axillary nerves.

Demographic data were collected on patient history including mechanism of injury and duration of symptoms (Table I). Selection for surgical treatment was based on pain and or weakness and limited function. Patients analyzed in this

study were those with weakness, pain, and electromyographic evidence of suprascapular nerve injury (Fig. 4). All patients completed standardized questionnaires and underwent physical examination with careful attention to active and passive motion and strength.

**SURGICAL PROCEDURE AND REHABILITATION**

Arthroscopic surgery was performed with the patient in a Beach-chair position (Tenet Tmax Beach Chair, Tenet Medical Engineering, Calgary, CN) following interscalene nerve blockade and administration of parenteral prophylactic antibiotics. An articulated hydraulic arm holder facilitated positioning of the arm for arthroscopy and arthroscopic rotator cuff repair (Spider Arm Holder, Tenet Medical Engineering, Calgary, CN). (Fig. 5).

Routine arthroscopic evaluation was performed in order to rule out comorbid pathology followed by a modified acromioplasty. Care was taken to preserve the coracoacromial ligament so as to prevent the risk of increased superior displacement of the humeral head by removal of this stabilizing barrier.

In all cases, a massive rotator cuff tear with marked medial and inferior retraction of the supraspinatus and infraspinatus

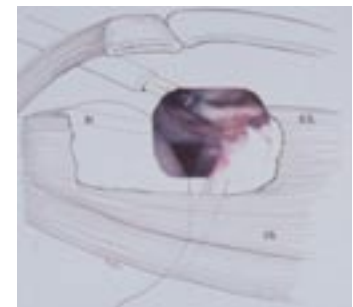


Figure 6. Massive rotator cuff tear with medial retraction of the supraspinatus precluding direct reinsertion of the humeral head. (See text for explanation.)

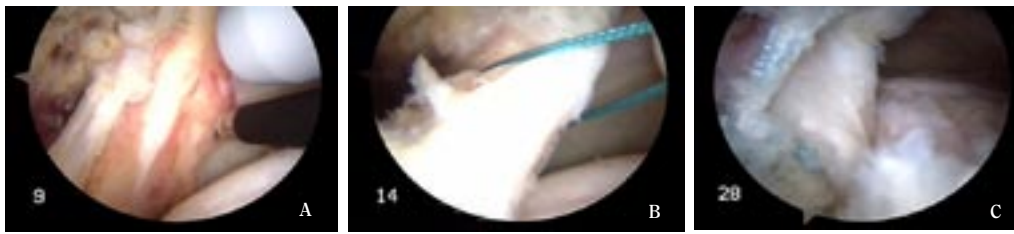


Figure 7A. Arthroscopic view of posterior retraction of the infraspinatus as seen through the lateral portal.  
 Figure 7B. Arthroscopic mobilization of the infraspinatus tendon.  
 Figure 7C. Arthroscopic repair of the infraspinatus tendon in to the posterior-superior greater tuberosity. (See text for explanation).

respectively was identified (Fig. 6). Arthroscopic repair was performed by placing the arthroscope in a lateral portal so that the entire posterior extent of the tendon tear could be visualized. The tendon was then mobilized using a radiofrequency probe (Vapr<sup>®</sup>, Mitek, Johnson and Johnson, Norwood, MA). The tendon tear was then repaired using a margin-convergence method as described by Burkhart along with direct reinsertion of the tendon in bone, or by partial reinsertion of the posterior component of the tendon tear if the supraspinatus was irreparable (Figs. 7A-C).<sup>9,10</sup> After repair an intraarticular pain catheter was placed for postoperative pain control (Painbuster<sup>™</sup>, DonJoy Orthopaedics, Carlsbad, CA).

All patients were then placed in a shoulder immobilizer with an external rotation pillow (Ultrasling<sup>™</sup>, DonJoy Orthopaedics, Carlsbad, CA) in order to protect the posterior component of the tendon repair.

**REHABILITATION PROTOCOL**

Patients remained in the shoulder immobilizer with an external rotation pillow for six weeks and no therapy was performed during this time period. After six weeks active motion was permitted for daily living activities. Gentle assisted range of motion was performed and strengthening was delayed until four months after the surgical procedure.

**POSTOPERATIVE ASSESSMENT**

Between four and six months postoperatively electrodiagnostic studies were repeated by the same experienced neurologist who performed the preoperative study. At a minimum of one year after surgery all patients answered a questionnaire and were examined.

**RESULTS**

Twenty-six of the two hundred sixteen patients (26/216) with rotator cuff tears were identified to have a massive tear associated with moderate to severe fatty muscle atrophy of the supraspinatus and infraspinatus.<sup>15</sup> Of the twenty six patients with massive rotator cuff tears, 14 (54%) were identified to have a peripheral nerve injury by electrodiagnostic study. Seven of the twenty-six patients (38%) had isolated SSN injury, 4 of 26 (15%) had axillary nerve injury, 2 of

26 (7%) had an associated upper trunk brachial plexus injury, and 1 of 26 (4%) had a cervical radiculopathy.

The seven patients with isolated suprascapular nerve injury consisted of six men and one woman. One patient was found to have an irreparable rotator cuff tear and was therefore not included

in the analysis of this paper. This patient later underwent a latissimus dorsi transfer. The preoperative patient data on the remaining six patients is summarized in Table I. Preoperative and postoperative function are summarized in Table II.

In the six patients who underwent surgery, five were men and one was a woman; all sustained their injury from a traumatic fall. The average duration of time that elapsed from the date of injury to surgery was 8 months (range 2-12). There were three right and three left shoulders, and 83% affected the dominant extremity. One patient had undergone a prior failed open rotator cuff repair. The mean age was 57.3 years (range 41-73). All patients had pain as well as weakness and lag signs consistent with a massive rotator cuff tear. Average active flexion was 117° (range 70-140°) and active external rotation was 16° (range -20-50°). The average difference between passive and active external rotation with the arm at the side was 28° (range 15-50°). This constitutes the degree of external rotation lag (Table II).

In the six patients who had a tendon tear which could be partially or completely repaired, the tear involved the entire supraspinatus and infraspinatus and had a maximum diameter in the anterior-posterior dimension of greater than 5 cm. Tendon quality was such that repair of the posterior component, the infraspinatus, was possible after arthroscopic release. The infraspinatus tendon was then repaired to the superior and posterior greater tuberosity, thus transposing it superiorly and laterally. In one case, an associated margin-convergence closure was possible by repairing the infraspinatus to the supraspinatus.

In the six patients who underwent either partial or complete arthroscopic repair, follow-up EMG/NCV after six months demonstrated recovery of the suprascapular nerve palsy that correlated with complete pain relief and marked improvement in function at one year minimum follow-up (Figs. 8A-C).

**Table II. Patient function before and after surgical repair of tendon.**

Patient	PREOP						POSTOP					
	AFLEX	PFLEX	PER	ER LAG	ER STR.	ABD STR	AFLEX	PFLEX	PER	ER LAG	ER STR.	ABD STR
DC	110	140	40	30	4-	4	140	140	40	5	4+	4+
GL	110	140	60	40	4	4+	140	140	60	5	4+	5
RB	130	160	40	10	4+	4	160	160	40	0	5	5
EB	140	160	30	50	4-	4	140	160	30	10	4+	4+
KB	70	140	20	15	4	4	130	140	20	0	4+	4+
GG	140	160	70	20	4-	4	150	160	70	5	4+	4+

NOTOR NERVE CONDUCTION						
NERVE	STIM	RECORD	DIET	LATENCY	CV	AMP
Suprascapular (needle recording)						
EB's pain		suprascapular	flex	2.4ms		11ms
EB's pain		infraspinatus	flex	1.6ms		11ms

ELECTROMYOGRAPHY			
MUSCLE	AT REST	MOTOR UNIT	RECRUITMENT
suprascapular	nl	nl	full
infraspinatus	nl	moderately enlarged	mod decrease
rhomboids	nl	nl	full
teres major	nl	nl	full
deltoid	nl	nl	full
trapezi	nl	nl	full

COMMENT ON ELECTROMYOGRAPHY: There is evidence of chronic denervation and reinnervation in the left infraspinatus muscle. Active denervation is no longer present.

DISCUSSION: There has been improvement in left infraspinatus muscle function since our study of 12/5/03. The degree of further recovery, if any, was not heralded from the study.

FRANK A. POTTS, M.D.

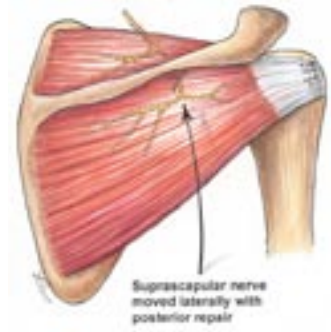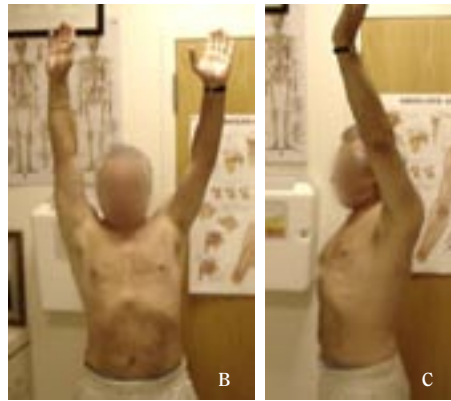


Figure 8A. Postoperative EMG and NCV study showing recovery of the suprascapular nerve four months after arthroscopic partial tendon repair.

Figure 8B. Postoperative flexion in a patient (EB).

Figure 8C. Postoperative flexion in the same patient.

Figure 9. Mechanism of recovery of suprascapular nerve by relieving traction around the base of the scapular spine with infraspinatus tendon repair.

## DISCUSSION

Although this is a retrospective study, we were able to identify a specific cohort of patients who had a massive rotator cuff tear in association with SSND. This association has been recognized previously by Albritton and coworkers; however, the incidence of this condition has not been clearly defined.<sup>1,2</sup> Our experience was that over a period of time slightly greater than one year, 7 of 216 patients (3%) had this condition. If one further narrows this down to a cohort of patients with massive tendon tears and fatty muscle replacement, then the incidence is much higher (7 of 26 or 38%). This would suggest that the degree of tendon retraction may be a cause of SSND through traction on the nerve either at the scapular notch or around the base of the spine of the scapula (Fig. 1). Albritton and coworkers suggested this phenomenon from their anatomic studies.<sup>1</sup>

We also observed that all of our seven patients with a massive rotator cuff tear and SSND had in common a traumatic fall associated with the onset of symptoms. Therefore, it is possible that SSND occurs as a sudden event due to a traumatic tendon tear with marked retraction.

We also observed an association of other peripheral nerve lesions with massive rotator cuff tear including axillary neuropathy, brachial plexopathy, and cervical radiculopathy. Vad and coworkers<sup>37</sup> had also observed this phenomenon.

Based on our observation of a high incidence of SSND with massive rotator cuff tears, we were able to validate our first hypothesis that SSND is associated with massive rotator cuff tears. Furthermore, it would seem that routine electrodiagnostic analysis is a reasonable component of preoperative evaluation in these patients.

We were also able to validate the second hypothesis in our study as arthroscopic repair of the massive rotator cuff tears significantly improved function and pain in our patients, and this correlated with electrical recovery of SSND after a minimum of four months following arthroscopic repair. We believe that this recovery principally occurred by relieving tension on the suprascapular nerve as it courses around the base of the spine of the scapula. Since the infraspinatus is repaired in a more superior and lateral position, the nerve is moved laterally away from the scapula spine around which is tethered (Fig. 9). We also believe this may be an explanation for the success of partial repair of a massive rotator cuff tear since the neurogenic cause of pain and weakness is relieved with the repair. This supports Burkhart's concept of partial arthroscopic repair of massive rotator cuff tears.<sup>8,11</sup>

From our observations we now recommend obtaining an electrodiagnostic study in all patients with a massive rotator cuff tear and marked weakness of abduction and external rotation, especially if this follows a known trauma such as a fall. If the EMG and NCV analysis shows SSND, we believe arthroscopic repair is indicated since all of our patients had marked improvement of pain and function and this correlated with reversal of SSND.

## References

1. Albritton, M. J.; Graham, R. D.; Richards, R. S., 2nd; and Basamania, C. J.: An anatomic study of the effects on the suprascapular nerve due to retraction of the supraspinatus muscle after a rotator cuff tear. *J Shoulder Elbow Surg*, 12(5): 497-500, 2003.
2. Albritton, M. J.; Graham, R. D.; Richards, R. S., 2nd; Mallon, W. J.; and Basamania, C. J.: The association of suprascapular neuropathy with massive rotator cuff tears. *American Shoulder and Elbow Surgeons 19th Annual Meeting, Pebble Beach, CA*, 2002.
3. Bennett, W. F.: Arthroscopic repair of massive rotator cuff tears: a prospective cohort with 2- to 4-year follow-up. *Arthroscopy*, 19(4): 380-90, 2003.
4. Bigliani, L. U.; Dalsey, R. M.; McCann, P. D.; and April, E. W.: An anatomical study of the suprascapular nerve. *Arthroscopy*, 6(4): 301-5, 1990.
5. Burkhart, S. S.: Arthroscopic treatment of massive rotator cuff tears. *Clin Orthop*, (390): 107-18, 2001.
6. Burkhart, S. S.: Arthroscopic treatment of massive rotator cuff tears. Clinical results and biomechanical rationale. *Clin Orthop*, (267): 45-56, 1991.
7. Burkhart, S. S.: Biomechanics of rotator cuff repair: converting the ritual to a science. *Instr Course Lect*, 47: 43-50, 1998.
8. Burkhart, S. S.: Partial repair of massive rotator cuff tears: the evolution of a concept. *Orthop Clin North Am*, 28(1): 125-32, 1997.
9. Burkhart, S. S.: The principle of margin convergence in rotator cuff repair as a means of strain reduction at the tear margin. *Ann Biomed Eng*, 32(1): 166-70, 2004.
10. Burkhart, S. S.; Athanasiou, K. A.; and Wirth, M. A.: Margin convergence: a method of reducing strain in massive rotator cuff tears. *Arthroscopy*, 12(3): 335-8, 1996.
11. Burkhart, S. S.; Nottage, W. M.; Ogilvie-Harris, D. J.; Kohn, H. S.; and Pachelli, A.: Partial repair of irreparable rotator cuff tears. *Arthroscopy*, 10(4): 363-70, 1994.
12. DeLisa, J.: Manual of nerve conduction velocity. Edited, Raven Press, 1987.
13. Galatz, L. M.; Ball, C. M.; Teefey, S. A.; Middleton, W. D.; and Yamaguchi, K.: The outcome and repair integrity of completely arthroscopically repaired large and massive rotator cuff tears. *J Bone Joint Surg Am*, 86-A(2): 219-24, 2004.
14. Gerber, C.; Fuchs, B.; and Hodler, J.: The results of repair of massive tears of the rotator cuff. *J Bone Joint Surg Am*, 82(4): 505-15, 2000.
15. Goutallier, D.; Postel, J. M.; Bernageau, J.; Lavau, L.; and Voisin, M. C.: Fatty muscle degeneration in cuff ruptures. Pre- and postoperative evaluation by CT scan. *Clin Orthop*, (304): 78-83, 1994.
16. Gschwend, N.; Ivosevic-Radovanovic, D.; and Patte, D.: Rotator cuff tear--relationship between clinical and anatomopathological findings. *Arch Orthop Trauma Surg*, 107(1): 7-15, 1988.
17. Harryman, D. T., 2nd; Mack, L. A.; Wang, K. Y.; Jackins, S. E.; Richardson, M. L.; and Matsen, F. A., 3rd: Repairs of the rotator cuff. Correlation of functional results with integrity of the cuff. *J Bone Joint Surg Am*, 73(7): 982-9, 1991.
18. Hawkins, R. J.; Misamore, G. W.; and Hobeika, P. E.: Surgery for full-thickness rotator-cuff tears. *J Bone Joint Surg Am*, 67(9): 1349-55, 1985.
19. Hertel, R.; Ballmer, F. T.; Lombert, S. M.; and Gerber, C.: Lag signs in the diagnosis of rotator cuff rupture. *J Shoulder Elbow Surg*, 5(4): 307-13, 1996.
20. Jones, C. K., and Savoie, F. H., 3rd: Arthroscopic repair of large and massive rotator cuff tears. *Arthroscopy*, 19(6): 564-71, 2003.
21. Lo, I. K., and Burkhart, S. S.: Arthroscopic repair of massive, contracted, immobile rotator cuff tears using single and double interval slides: technique and preliminary results. *Arthroscopy*, 20(1): 22-33, 2004.
22. Post, M.; Silver, R.; and Singh, M.: Rotator cuff tear. Diagnosis and treatment. *Clin Orthop*, (173): 78-91, 1983.
23. Rengachary, S. S.; Burr, D.; Lucas, S.; and Brackett, C. E.: Suprascapular entrapment neuropathy: a clinical, anatomical, and comparative study. Part 3: comparative study. *Neurosurgery*, 5(4): 452-5, 1979.
24. Rengachary, S. S.; Burr, D.; Lucas, S.; Hassanein, K. M.; Mohn, M. P.; and Matzke, H.: Suprascapular entrapment neuropathy: a clinical, anatomical, and comparative study. Part 2: anatomical study. *Neurosurgery*, 5(4): 447-51, 1979.
25. Rengachary, S. S.; Neff, J. P.; Singer, P. A.; and Brackett, C. E.: Suprascapular entrapment neuropathy: a clinical, anatomical, and comparative study. Part 1: clinical study. *Neurosurgery*, 5(4): 441-6, 1979.
26. Rockwood, C. A., Jr.; Williams, G. R., Jr.; and Burkhead, W. Z., Jr.: Debridement of degenerative, irreparable lesions of the rotator cuff. *J Bone Joint Surg Am*, 77(6): 857-66, 1995.
27. Sunderland, S.: Anatomical features of nerve trunks in relation to nerve injury and nerve repair. *Clin Neurosurg*, 17: 38-62, 1970.
28. Sunderland, S.: The anatomy and physiology of nerve injury. *Muscle Nerve*, 13(9): 771-84, 1990.
29. Sunderland, S.: Stretch-compression neuropathy. *Clin Exp Neurol*, 18: 1-13, 1981.
30. Vad, V. B.; Southern, D.; Warren, R. F.; Altchek, D. W.; and Dines, D.: Prevalence of peripheral neurologic injuries in rotator cuff tears with atrophy. *J Shoulder Elbow Surg*, 12(4): 333-6, 2003.
31. Warner, J. P.; Krushell, R. J.; Masquelet, A.; and Gerber, C.: Anatomy and relationships of the suprascapular nerve: anatomical constraints to mobilization of the supraspinatus and infraspinatus muscles in the management of massive rotator-cuff tears. *J Bone Joint Surg Am*, 74(1): 36-45, 1992.