

TREATMENT OF ELBOW FRACTURES: A HISTORICAL PERSPECTIVE

JOB DOORNBURG, MS, JESSE JUPITER, MD

MASSACHUSETTS GENERAL HOSPITAL

“There is no class of injuries so frequently productive of discontent, and perhaps so often the cause of litigation, as traumatic lesions of the elbow joint”

Henry Jacob Bigelow, Massachusetts General Hospital, Boston 1868

INTRODUCTION

The contemporary difficulties in the management of traumatic and reconstructive problems involving the elbow are equally reflected through antiquity as one investigates the history of medical and surgical care of musculoskeletal problems. As with so many areas of orthopaedics, the literature of the past reflects the ingenuity, frustrations, ego, and personal self-aggrandizement of physicians, irrespective of the era in which they practiced the art and science of medicine.

CLOSED REDUCTION AND SPLINTING

Some of the earliest examples of traumatic injuries involving the upper limb were found in the archeological efforts in the Nubian Desert by Sir Grafton Elliot Smith (1871-1937)¹. Fractures were common findings and splints were recovered made of bamboo, reeds, woods or bark and padded with linen. It is of interest that several thousand years later similar splints were described in Europe known as Joncs (reeds)¹.



Figure 1. Reduction of elbow luxation²⁴. Wall painting. Tomb of Ipy, Egypt, 1200 B.C.⁵ (Reproduced by kind permission of The Metropolitan Museum of Fine Arts, New York City)

Mr. Doornberg is a Research Fellow, Orthopaedic Hand and Upper Extremity Service, Massachusetts General Hospital and Harvard Medical School, and PhD. Candidate, University of Amsterdam

Dr. Jupiter is Professor of Orthopaedic Surgery and Chief Orthopaedic Hand and Upper Extremity Service, Massachusetts General Hospital and Harvard Medical School, Boston, MA

Please address correspondence to:

Jesse Jupiter, MD
Massachusetts General Hospital
15 Parkman St., ACC 525
Boston, MA 02114

In 1862, a papyrus was found in a tomb in Thebes and sold to an American Egyptologist, Edwin Smith. It is thought to be the work of Imhotep, an architect and chief minister to king Zoser (c. 2800 BC). It represents a collection of 48 clinical records including careful description of reduction and splinting of fractures of the upper arm.²

Much of the discussion related to elbow trauma in early writings including those of the Greeks, Romans, Chinese, and Japanese were related to methods of reductions of dislocations and immobilization. Undoubtedly, more than a few elbow dislocations were in reality fractures! Hippocrates observed that an elbow dislocation, after reduction, should be bandaged slightly greater than at a right angle as this should be the most functional position should ankylosis occur⁶. Hippocrates noted: *“If ankylosis should eventually develop, an arm ankylosed in the extended position would be better away (i.e. amputated) for it would be of great hindrance and of little use to the patient.”*

Figure 2. Medical skills in ancient Greece. Achilles bandaging Patroclus. Chalice design by Sosias.



Hippocrates' text warned of the fact that elbow dislocations could be difficult to reduce, with complications being commonplace: *“Sometimes the head of the humerus itself is fractured at the epiphysis, yet this, though it may seem a very serious injury, is much less so than injuries of the elbow joint.”*

PLASTER

In 970 A.D., the Persian Abu Mansur Muwaffak suggested that fractures and other bony injuries should be coated with plaster. The Arabic physicians had discovered that the addition of water to a soft powder of anhydrous calcium sulfate produced the firm hydrated crystalline form. This was observed centuries later by William Eton in 1798, former British consul to Turkey and soon became standard in Europe.^{2,7} A Dutch Army surgeon Antonius van Mathysen developed the plaster bandage with his book published in 1852.^{8,9} A precursor of the plaster bandage was recorded by the famous English surgeon and anatomist

William Cheselden, who, as a schoolboy sustained an elbow fracture that was treated in this manner:¹

*“I thought of a much better bandage which I learned from Mr. Cowper, a bone setter at Leicester, who set and cured a fracture of my own cubit when I was a boy at school. His way was, after putting the limb in a proper posture, to wrap it up in rags dipped in the whites of eggs and a little wheat flour mixed. This drying grew stiff and kept the limb in good posture. And I think there is no way better than this in fractures, for it preserves the position of the limb without strict (tight) bandage which is the common cause of mischief in fractures.”*⁷

Yet the plaster support was not universally accepted in the 19th century, particularly in England and America. Hugh Owen Thomas and Robert Jones thought it risky. Jones suggested: *“Nothing so barbarous as Plaster-of-Paris is used any longer”*.

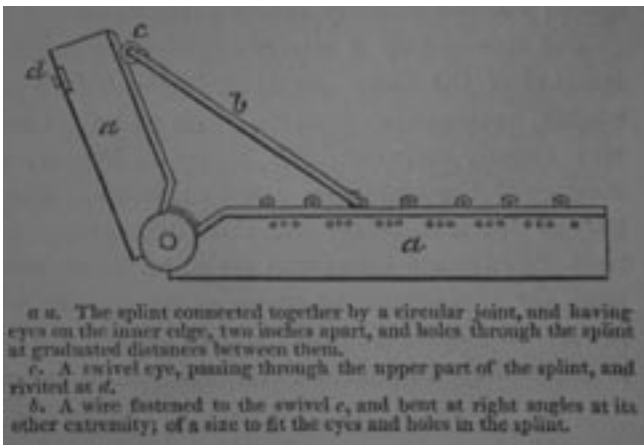


Figure 3. Dr. Kirkbride's moveable angular splint.¹⁰



Figure 4. Static progressive splinting in 1517. Hans van Gersdorff: turnbuckle correction for elbow flexion contracture

SPLINTING

Thus the 19th century saw the continued use of splints, many custom made for the elbow joint and advocated with zeal by its developer. Some splints such as that devised by Rose, Kirkbride, or Welch offered adjustable hinges which could be used to stretch out elbow contractures.

Of interest is perhaps the earliest turnbuckle splint, devised as early as 1517 by Hans von Gersdorff, who termed his splint the *“appliance for the crooked arm.”*¹¹

RECOGNITION

The pre-roentgenogram nineteenth century also witnessed a more widespread recognition that many elbow injuries involved fractures rather than dislocations. Dupuytren noted this in the early part of the century:¹² *“There is nothing so common as to see a fracture of the lower end of the humerus, immediately above the elbow joint, mistaken for a dislocation*

backward.” He advised: *“The principal sign by which fracture may be distinguished from dislocation is crepitus”*. This *“valuable sign ... is often very much masked, or even hidden, by the presence of swelling”*.

Malgaigne also noted that *“In dislocations the articulation is destroyed, and flexion or extension are impracticable, whereas in fracture it is intact, and the movements are probably in part preserved”*.

Dupuytren described numerous cases of management of distal humerus fracture illustrated well in this example:¹³

“All the signs which resembled dislocation were easily explained by the seat of the fracture: for, the continuity of the humerus being broken, its lower articulating extremity no longer presented their natural support to the radius and ulna, and the olecranon consequently drawn upwards by the tonic contraction of the triceps...”

“On the day that the above accident happened it was found impracticable to obtain entire reduction, on account of the pain which the attempt produced, and especially in consequence of the great swelling. I was, therefore, obliged to place the arm, semiflexed, on some pillows, which were placed horizontally; and directed that the affected parts should be kept wet with Goulard's wash. The patient was also largely bled, and low diet and an anodyne draught prescribed...”

“Second day. The reduction being accomplished, the arm was again placed on pillows as before: some graduated compresses were applied around the lower extremity of the arm, so as to correspond to the two osseous prominences, and to replace the fingers, by the pressure of which they had been forced into position. Support was also afforded by two long compresses, and other parts of the apparatus, which had been prepared by being wetted with a solution of acetate of lead in cold water. Lastly, the two lateral pads were folded on themselves at their lower extremity, so that in tightening the apparatus the splints might be forced against the graduated compresses, and thus press in opposite directions the olecranon process and the upper extremity of the lower fragment.

“On the thirty-third day the apparatus was finally removed, there being a good union, unattended by deformity; and on the forty-fifth, D. left the hospital having already considerable power in flexion and extension of the joint”.

It is noteworthy that during Dupuytren's era not all eminent physicians agreed regarding differential diagnosis. Bigelow at the Massachusetts General Hospital stated:

“I have found an opposite error, however, by far the most frequent, namely - a dislocation of both bones backwards has been supposed to be a fracture. The sources of embarrassment are found in the proximity of the fracture to the joint, in the rapidity with which swelling occurs, and in the striking similarity of the symptoms which characterize the two accidents”.

Bigelow himself favored custom splints created in a manner not too dissimilar to those described by Arab physicians centuries before which was termed gutta percha:

“Whatever material is employed, a pretty large pledget of fine cotton batting ought to be laid in front of the elbow joint

to prevent the roller from excoriating the delicate and inflamed skin and great care should be taken to protect the bony eminence...”

“At a very early day, so early, indeed as the seventh or eight day, the splint should be removed, and, while the fragments are steadied, gentle passive motion should be inflicted upon the joint”.

Bigelow also documented examples of cases treated:



Figure 5. Bigelow's splint

“A woman, living in this city, age 44, fell upon the sidewalk in January, 1850, striking upon her right elbow. I saw her a few minutes after the accident, but the parts about the joint were already considerably swollen, and it was not without difficulty that the diagnosis was made out. The forearm was slightly flexed upon the arm, and pronated. On seizing the

elbow firmly, a distinct motion was perceived above the condyles, and a crepitus. I could also feel, indistinctly, the point of the upper fragment. While moderate extension was made upon the arm, the condyles were pressed together, when it was apparent that they had been separated. On removing the extension they again separated, and the olecranon drew up. She was in a condition of extreme exhaustion, and the bones were easily placed in position.

“An angular splint was secured to the limb, and every care used to support the fragments completely, but gently.

“From this date until the conclusion of the treatment, the dressings were removed often, and the elbow moved as much as it was possible to move it.

“Seven months after the accident, the elbow was almost completely ankylosed at a right angle. The fingers and wrist also were quite rigid. Six years later, the ankylosis had nearly disappeared; she could now flex and extend the arm almost as much as the other; the wrist joint was free, and the fingers could be flexed, but not sufficiently to touch the palm of the hand. The line of fracture through the base could be traced easily, but the humerus was not shortened. There was, moreover, much tenderness over the point of fracture through the base, and at other points. Occasionally, a slight grating was noticed in the radio-humeral articulation. She experienced frequent pains in the arm, and especially along the back and radial border of the ring finger. During the first year or two after the accident, the arm perished very much, but although the hand remained weak, the muscles were now well developed”.

MALPRACTICE

The treatment of the elbow trauma during the nineteenth century was fraught with unfortunate outcomes not the least of which led to medical malpractice cases. Bigelow documents a few excerpts:

“A case was recently tried in the Supreme Court at Brooklyn, N.Y., in which, after a simple fracture at this point, the arm, being dressed with splints and bandages, the little finger sloughed off, in a condition of dry gangrene, and the adjacent parts of the hand were attacked with humid mortification. Drs. Parker and Prince believed that this serious accident was the result of bandages applied too tightly and suffered to remain too long, while Drs. Valentine Mott, Rogers Wood, Ayres, Dixon, and others, believed that the gangrene might have been due to other causes over which the surgeon had no control”

“Warren Co., Ky. A boy, ten years old, had broken his arm above the condyles, and his parents having employed a surgeon residing at some distance, the dressings were applied, and directions given to send for the surgeon whenever it became necessary. The parents saw the arm swell excessively, and knew that the boy was suffering very much, but did not notify the surgeon until the tenth day, when the hand was found to be in a condition of mortification, and at length

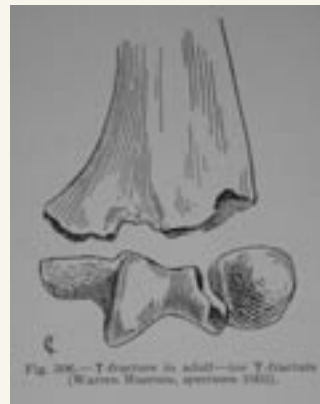

Figure 6. Low T-fracture of the distal humerus (from Cotton, 1910)

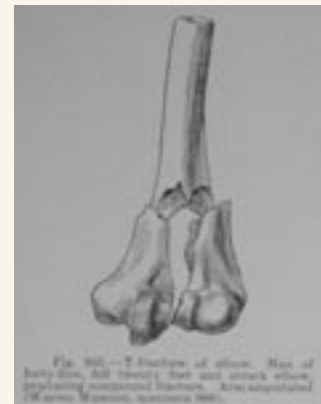

Figure 7. T-fracture of the distal humerus (from Cotton, 1910)

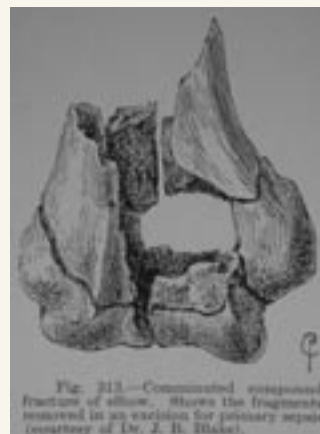

Figure 8. Comminuted fracture of the distal humerus (from Cotton, 1910)

amputation became necessary.

“Long afterward, in the year 1851, when the boy became of age, he prosecuted his surgeon, but with no result to either party beyond the payment of their respective costs”.

THE MAJOR ADVANCES OF THE NINETEENTH CENTURY

The nineteenth century brought one of the major advances in medicine, namely the development of ether anesthesia which was first demonstrated at the Massachusetts General Hospital in 1846.¹⁴ This not only permitted operative treatment but also led to the recommendation of some to consider manipulation as a management option for the elbow rendered stiff following traumatic injury and resultant treatment. Bigelow noted:

“The introduction of etherization by preventing the pain, gives us, in the opinion of Dr. Warren, the means of overcoming the resistance. By its aid, he has restored the motion of a considerable number of ankylosed elbow(s), and has successfully applied this same measure to other joints...”

Another major development in the nineteenth century to influence the management of elbow trauma was that of the Roentgen ray. As stated by Scudder, this invention¹⁵ *“made the knowledge of fractures more exact and their treatment less complicated. The attention of the student is diverted from theories and apparatus to the actual conditions that exist in the fractured bone, and he is encouraged to determine for himself how to meet the conditions found in each individual case of fracture”.*

Prior to the x-ray, identification of fracture patterns were

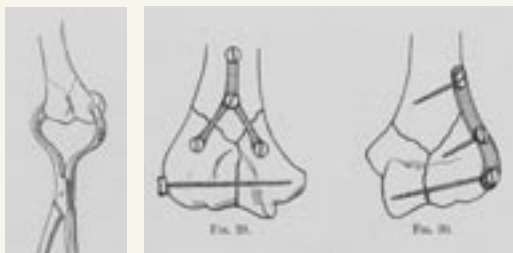


Figure 9.
Reduction Y-
fracture (from
Lambotte, 1913)

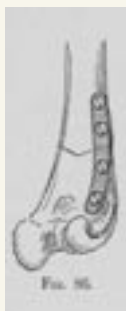

Figure 10.
Internal Fixation Y-fracture (from Lambotte, 1913)

Figure 11.
Plate fixation supracondylar
fracture (from Lambotte, 1913)

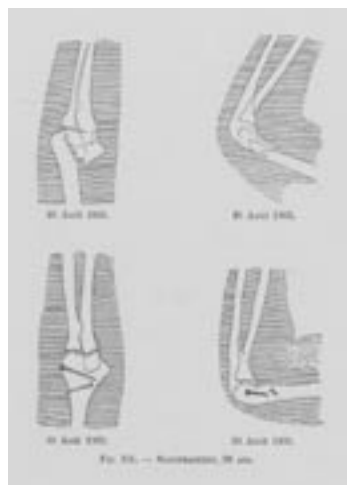

Figure 12.
Open reduction and internal fixation
of intra-articular distal humerus frac-
ture (from Lambotte, 1913)

determined almost exclusively from postmortem case or open fractures. Many of the descriptions and drawings are consistent with contemporary classifications.

The third scientific advance of the nineteenth century, which led to major developments in elbow injuries, was that of antisepsis. Prior to this, surgery was primarily performed for open fractures and in most cases for removal of fragments, illustrated by Dr Stone with this case of a 26-year old woman with open intercondylar comminuted fracture of the distal humerus:¹⁶

“On introduction of the finger, several detached pieces of bone could be felt, and they were removed with the fingers. It was ascertained that the humerus had been broken from the condyles, and that these last had been split asunder into the joint. Operation: The lower end of the humerus was made to project through the wound, and sawed off smoothly. The external cutaneous nerve lay exposed in the wound, and was drawn aside during the sawing. A cut was then made, three to four inches long, through the triceps muscle to the olecranon and by seizing the broken condyles separately with a pair of forceps, I was enabled; by twisting and dissecting, to remove them without injury to the ulnar nerve. The wound was dressed with wet lint, and she was put in bed...”

“Nov 4th 1850. 4th day- Suppuration beginning. 6th day- profuse -Considerable swelling. 7th day- Granulation over wound. 13th day- The lower extremity of the humerus projects against the integuments, on the outer side of the arm. This was remedied by lateral splints of pasteboard. 46th day- Made pasteboard splint, bent at right angle, and adapted to the elbow, and perforated at the olecranon for the discharge of matter. 67th day- pain and swelling in the humerus, resembling periostitis, which has been relieved by painting the part with iodine, and internal use of the hydriodate of potash. A tin rectangular splint is now used to steady the limb. 96th day- The wounds are completely healed. She constantly exercises the arm, and can bend the fore-arm at a right angle with the humerus”.

CONCLUSION

Antisepsis, anesthesia, and the x-ray enabled ingenious surgeons such as Dr. Albin Lambotte to bring us into the modern era of the management of elbow trauma. His carefully documented case studies reveal operative approaches and implants very much resembling those of today.¹⁷⁻¹⁹ We are fortunate to be able to have had the wisdom and experience of all of these giants of medicine who have established the approaches to diagnosis and management which we use today. Lambotte coined the term osteosynthesis and led us into the twenty first century, the era of open reduction and internal fixation.




Figure 13.
With good clinical outcome (from Lambotte, 1913)

References

1. **Browner BD, Green NE, Swiontkowski MF.** Skeletal trauma [and] Skeletal trauma in children. In. 3rd ed. [New York, N.Y.]: W.B. Saunders; 2003. p. 1 CD-ROM.
2. **Le Vay D.** The history of orthopaedics : an account of the study and practice of orthopaedics from the earliest times to the modern era. Carnforth, Lancs, UK ; Park Ridge, N.J., USA: Parthenon Pub. Group; 1990.
3. **Breasted JH, New-York Historical S, Library.** The Edwin Smith surgical papyrus. Chicago, Ill.,: The University of Chicago Press; 1930.
4. **Beasley AW.** The origins of orthopaedics. J R Soc Med 1982; 75(8): 648-55.
5. **Davies NdG, Metropolitan Museum of Art Egyptian E.** Two Ramesside tombs at Thebes. New York; 1927.
6. **Hippocrates, Adams F.** The genuine works of Hippocrates. London: Printed for the Sydenham society; 1849.
7. **Monro JK.** The history of plaster-of-paris in the treatment of fractures. Br J Surg 1936; 23: 257-266.
8. **Mathijssen A.** Nieuwe Wijze van Aanwending van het Gips-Verband bij Beenbreuken. Haarlem: J.B. van Loghem; 1852.
9. **Mathijssen AM.** Der Gyps-Verband und seine Anwendung bei Knochenbrüchen. Crefeld.: Kühler; 1857.
10. **Kirkbride. Kirkbride's Clinical Reports.** American Journal of the Medical Sciences 1835;vol XVI: 315.
11. **Von Gersdorff H.** Feldtbuch der Wundartzney. 1st ed. Strassburg: Getruckt durch Joanne Schott; 1517.
12. **Dupuytren G.** Lectures on Clinical Surgery, delivered in the Hotel-Dieu of Paris. Washington: Green; 1835.
13. **Dupuytren.** On the Injuries and Diseases of Bone. 1st ed. London: Sydenham Society; 1847.
14. **Bigelow HJ.** Insensibility during surgical operations produced by inhalation. Boston.,; 1846.
15. **Scudder CL, Cotton FJ.** The treatment of fractures. Philadelphia.,: W. B. Saunders; 1900.
16. **Stone.** Stone's Surgical Cases. New York Journal of Medicine 1851;VI: 30.
17. **Lambotte A.** L'intervention opératoire dans les fractures récentes et anciennes envisagée particulièrement au point de vue de l'ostéo-synthèse avec la description de plusieurs techniques nouvelles. Bruxelles: Henri Lamertin Libraire-Éditeur; 1907.
18. **Lambotte A.** Chirurgie opératoire des fractures. Paris: Masson & Cie Éditeurs; 1913.
19. **Lambotte A.** The Beginning of Internal Fixation of Fractures (osteosynthesis) in Belgium. 2nd ed. Bruxelles/Brussel: ASBL Acta Orthopaedica Belgica VZW; 1997.