

# DESIGN RATIONALE AND PRECLINICAL TESTING OF AN ANTERIOR INTERBODY FUSION DEVICE

PAUL A. GLAZER, MD, AND STEPHEN D. COOK, PhD

DEPARTMENT OF ORTHOPAEDICS, BETH ISRAEL DEACONESS MEDICAL CENTER, BOSTON MA

## ANTERIOR LUMBAR INTERBODY FUSION

Anterior lumbar interbody fusion (ALIF) is a surgical technique used to treat a variety of spinal disorders. Anterior discectomy and fusion allows a direct enhancement of disc height with restoration of lumbar lordosis. This technique also accomplishes an indirect neuroforaminal decompression. Furthermore, anterior interbody spinal fusion is associated with improved fusion rates as compared to posterior inter-transverse process fusions. The enhancement of fusion rates is believed to be due to the placement of the fusion mass under compression as compared to the posterior grafts, which are under tensile stress.

Disease processes which are treated with anterior lumbar interbody fusions include discogenic back pain, recurrent disc herniations, spondylolisthesis, spinal instability, scoliosis and deformity corrections, flatback syndrome, combined anterior/posterior procedures when the fusion extends to the lumbar spine or pelvis, and spondylosis. (1-6)

The success rate for ALIF varies widely in the literature with a number of different surgical approaches, devices, and bone graft options utilized. (7) The variable clinical success rates and presence of pseudarthrosis are often also attributed to patient risk factors (smoking, obesity, metabolic disorders, graft material).

Surgeons have attempted to perform stand-alone anterior fusions (without supplemental posterior instrumentation) with devices that enhance mechanical stability of the motion segment. (Figure 1)

Although fusion rates of 90% or higher for single level lumbar interbody fusions are reported, these rates may be 70% or potentially lower in the presence of risk factors. However, these stand-alone procedures have been found to have higher pseudarthrosis rates when multi-level fusions are attempted.

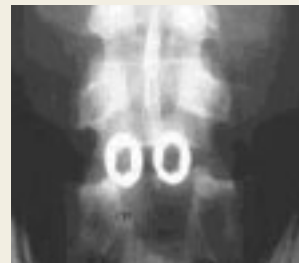**Dr. Paul Glazer** is Acting Director of Spinal Surgery, Department of Orthopaedic Surgery, Beth Israel Deaconess Medical Center, Boston, MA

**Dr. Stephen D. Cook** is Professor of Orthopaedic Surgery, Tulane University School of Medicine, New Orleans, LA.

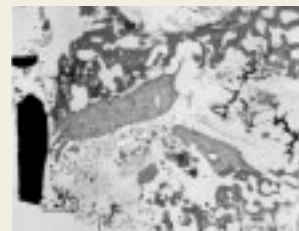Address correspondence to:

Paul A Glazer, MD, PC  
330 Brookline Ave CC2  
Boston Massachusetts 02215

pglazer@caregroup.harvard.edu



**Figure 1:**  
Post-op AP view of titanium cylindrical cages



**Figure 2:**  
Histology demonstrating necrotic bone and fibrous tissue from an explanted cylindrical cage which had developed a pseudarthrosis

Multi-level fusion procedures are now often performed with a combined anterior/posterior approach in order to attain satisfactory fusion rates.

## FUSION DEVICES AND TECHNIQUES

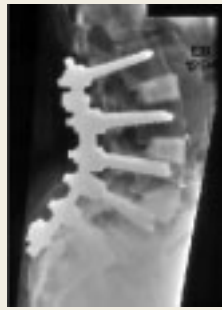Current anterior interbody fusion devices include: tricortical autograft, titanium cylindrical cages (e.g. Harms cage (Depuy-AcroMed, Cleveland, OH), BAK (Spine-Tech, Minneapolis, MN)), allograft cortical dowels, and femoral ring allograft.

Each of these surgical options has relative risks and benefits to their use. Tricortical autograft offers the highest fusion rates, but there is limited donor supply and significant graft site morbidity. The titanium cylindrical cages (e.g. Harms, BAK) allow a maintenance of lordosis, but there is difficulty assessing fusion because of metallic interference.


Histology of cages which have been surgically removed often demonstrates small areas of viable bone, but the slides frequently are dominated by areas of necrotic bone, fibrocartilage, and fibrous tissue. (Figure 2) The cylindrical cages are designed with small windows which allow for bony ingrowth from the adjacent vertebral endplates.

Allograft cortical dowels have the potential for biologic bony incorporation, however


their use is limited to L4-5 and L5-S1 via a direct anterior approach due to anatomic restrictions. Femoral ring allograft allows excellent lordosis restoration, but again there is difficulty



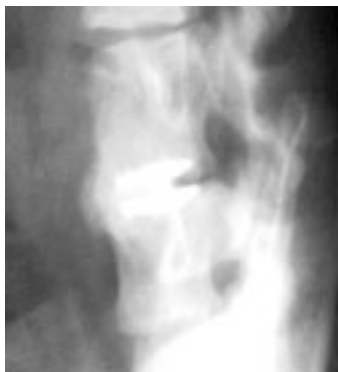**Figure 3:** Lateral radiograph of a multi-level fusion with allograft femoral rings supplemented with posterior instrumentation.



**Figure 4:** The evolution of the EBI Ionic vertebral body replacement device.



**Figure 5:** Final design of the EBI Ionic vertebral body replacement device.



**Figure 6:** Lateral radiograph of Grade 5 fusion in a monkey's spine with evidence of anterior remodeling with the Ionic vertebral spacer in place.

assessing fusion post-operatively, and the femoral rings often are supplemented with additional fixation because of their limited initial biomechanical stability. (Figure 3)

## EBI IONIC VERTEBRAL BODY REPLACEMENT SYSTEM

Given the limitations of the existing technology, the authors chose to participate in the creation of a new vertebral body replacement device with the following design criteria: improved post-operative plain radiographs and CT fusion visualization of the fusion mass, peripheral endplate coverage to reduce subsidence, and biomechanical strength. In addition, the new device needed to accommodate adequate bone graft volume and to allow for enhanced surface area contact with the adjacent vertebral bodies.

This implant was designed in conjunction with EBI, Inc. (Parsippany, NJ) The implant went through several design iterations. (Figure 4)

### PRECLINICAL STUDIES

The final design underwent stringent biomechanical testing. (Figure 5)

Static and dynamic testing was performed using FDA guidance documents and ASTM standards. The device alone, and as part of an anatomical construct, was tested. The Ionic device provides two times vertebral body crush strength and high fatigue strength. The design also allows deflection to strain the developing fusion mass. The columnar design allows a uniform stress transfer, accomplishing high ultimate and yield loads. Furthermore, the Ionic endplates cover a significant portion of the vertebral body; thus, there is minimal subsidence under high loads. The Ionic Anterior interbody spacer is currently available in variable heights (9mm – 56mm) and with 0 or 8 degrees of lordosis.

A preclinical in vivo study was performed using twenty adult pigtail monkeys. These animals underwent an anterior L<sub>5</sub>-L<sub>6</sub> fusion through a retroperitoneal approach. There were ten animals in each treatment group. The animals received either the Ionic device or an allograft femoral ring, used in combination with iliac crest bone graft. Five animals in each group were sacrificed at 12 and 26 weeks. No additional fixation was used.

The fusions were analyzed with monthly AP and lateral plain film radiographs, CT imaging at sacrifice, and mechanical testing (nondestructive). In addition, qualitative and quantitative histology and microradiography was performed. A grading scale was used to evaluate the presence of fusion.

| Grade | Presence of Fusion                  |
|-------|-------------------------------------|
| 0     | No healing                          |
| 1     | Consolidation                       |
| 3     | Bridging callus                     |
| 4     | Bridging callus with trabeculations |
| 5     | Evidence of remodeling              |

Mechanical testing of the fusion masses was performed in a nondestructive mode and measured the stiffness of the fusion mass. The fusion masses were tested in axial compression, lateral side-bending, as well as flexion and extension bending.

Results: Radiographically, the Ionic Fusion Device had an

improved incidence of bony fusion as compared to the femoral ring group. The mechanical data showed no significant differences between the groups. Histologically, the Ionic Fusion Device had a 86% incidence of bony fusion compared to 50% for Allograft Rings and was six times more likely to have a bony fusion.

#### **CLINICAL TRIAL**

Given the positive biomechanical and *in vivo* animal results observed, a clinical trial was begun in the US under FDA guidelines. The device has been now used in over 75 patients, without evidence of mechanical failure. The unique design of the EBI Ionic Anterior Interbody Spacer and accompanying instrumentation which has been developed allow the device to be placed anteriorly or laterally in the thoracic or lumbar spine. The following radiographs demonstrate its clinical effectiveness.

Patient A: Severe lower back pain with an L4-5 disc space

collapse in conjunction with a recurrent disc herniation. He underwent an anterior interbody fusion and placement of the Ionic Spacer. The lateral intra-op radiograph demonstrates the ease of fusion evaluation.

#### **PRE-OP LATERAL RADIOGRAPH.**

Intra-op lateral radiograph demonstrating disc height restoration accomplishing indirect neuroforaminal decompression and ease of visualization of anterior sentinel sign.

Patient B: Significant kyphoscoliosis s/p previous laminectomy for intra-dural tumor resection at the thoracolumbar junction:

Post-op radiographs demonstrating multi-level placement of the Ionic vertebral spacers which help restore anatomic lumbar lordosis and correct sagittal and coronal plane alignment.

Given our initially positive clinical experience, we believe that the EBI Ionic anterior vertebral body replacement device is an attractive option for anterior interbody fusion.

## **References**

1. **Blumenthal SL, Baker J, Dossett A, Selby DK.** The role of anterior lumbar fusion for internal disc disruption. *Spine* 1988;13:566-9.
2. **Calandruccio RA, Benton BF.** Anterior lumbar fusion. *Clin Orthop* 1964; 35:63-8.
3. **Chow, SP, Leong JC, Ma A, Yau AC.** Anterior spinal fusion for deranged lumbar intervertebral disc: A review of 97 cases. *Spine* 1980;5:452-8.
4. **Harmon PH.** Anterior excision and vertebral body fusion operation for intervertebral fusion. *Clin Orthop* 1963;26:107-27.
5. **McAfee PC.** Interbody fusion cages in reconstructive operations on the spine. *J Bone Joint Surg Am* 1999;81:859-80.
6. **Ray CD.** Threaded titanium cages for lumbar interbody fusions. *Spine*. 1997;22:667-80.
7. **Togawa D, Bauer TW, Brantigan JW, Lowery GL.** Bone graft incorporation in radiographically successful human intervertebral body fusion cages. *Spine* 2001;15:2744-50.