

# ADVANCES IN THE MANAGEMENT OF FRACTURES OF THE DISTAL HUMERUS AND THEIR SEQUELAE

L. PEARCE McCARTY, III MD, DAVID RING, MD, JESSE B. JUPITER, MD

DEPARTMENT OF ORTHOPAEDICS, MASSACHUSETTS GENERAL HOSPITAL, BOSTON MA

## INTRODUCTION

Articular fractures of the elbow remain among the most challenging injuries to treat. However, greater appreciation of the functional anatomy of the elbow, injury patterns, and technological advances in internal fixation and arthroplasty have substantially improved the potential for more functional outcomes. This review will highlight a number of contemporary issues related to fractures of the distal humerus and their sequelae, with particular emphasis on the contribution of the Orthopaedic Hand Service at the Massachusetts General Hospital.

## EPIDEMIOLOGY

Two factors are noteworthy in evaluating the incidence of fractures of the distal humerus. First, although distal humerus fractures are relatively uncommon, they demand technically difficult operative treatment, often with relatively high morbidity. As a result, clinical resource utilization in contemporary treatment algorithms is disproportionately greater than their incidence. Secondly, there has been a substantial increase in the number of these fractures occurring in older, osteoporotic patients. A Finnish study by Palvanen *et al.* reported that in 1970, the incidence of distal humerus fractures in women greater than 60 years of age was 12 per 100,000, whereas in 1995, the incidence was 28 per 100,000. Their data suggested a trend that would see a threefold increase in complex distal humerus fractures by 2030.<sup>1</sup> Distal humerus fractures in osteoporotic patients are also more complex. This notion is supported by a study by Pajarinev and Bjorkenheim, in which good or excellent results occurred in all 8 patients 40 years or

younger, while only 2 of 10 patients greater than 50 years in age had satisfactory results with comparable operative treatment.<sup>2</sup>

## FUNCTIONAL ANATOMY

The importance of the anatomic relationships of the trochlea to the olecranon in providing elbow stability has been highlighted in our experience with shearing articular fractures of the distal humerus.<sup>3,4</sup> Recognition and anatomic restoration of fractures involving the trochlea has resulted in predictable functional results without subsequent instability or arthrosis.

## CLASSIFICATION

While the Comprehensive Classification of the AO/ASIF<sup>5</sup> as well as that of the Orthopaedic Trauma Association has been well accepted worldwide for articular fractures, the complex anatomy of the distal humerus has required additional fracture definitions. The classification of Mehne and Matta, published in *Skeletal Trauma*,<sup>6</sup> provides a definition of the articular fracture based on its articular and skeletal involvement. Additionally, we have identified a unique pattern of injury, termed “multiplane” fracture, in which the trochlea is disrupted in both the sagittal and coronal planes.<sup>7</sup>

What has been of particular importance is our new classification of shearing fractures of the distal humerus. In our initial report on these injuries, we identified a shearing fracture involving the capitellum and trochlea, termed the “coronal shear” fracture.<sup>4</sup> We have expanded this classification to include six specific patterns of injury (Figure 1.).<sup>3</sup>

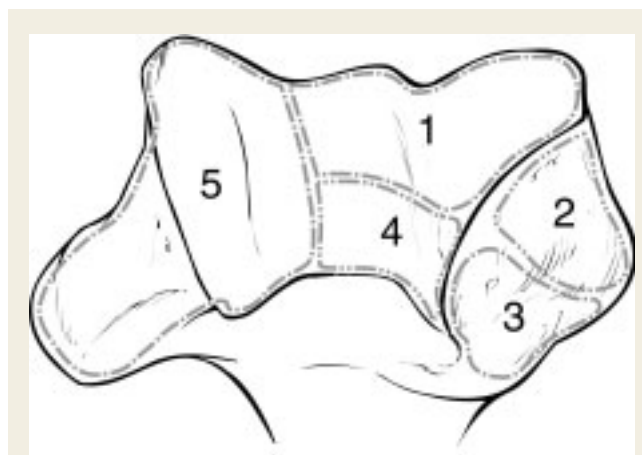
L. Pearce McCarty, III MD is a Resident, Harvard Combined Orthopaedic Residency Program, Boston, MA.

David Ring, MD, is an Instructor of Orthopaedic Surgery, Harvard Medical School, Director of Research, Hand and Upper Extremity Service, Department of Orthopaedic Surgery, Massachusetts General Hospital.

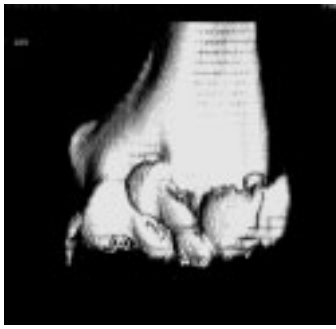Jesse B. Jupiter, MD, is a Professor of Orthopaedic Surgery, Harvard Medical School, Chief, Hand and Upper Extremity Service, Department of Orthopaedic Surgery, Massachusetts General Hospital.

Address correspondence to:

David Ring, MD  
Massachusetts General Hospital  
ACC 525  
15 Parkman St.  
Boston, MA 02114  
Tel: 617-724-3953  
Fax: 617-726-8214  
Email: dring@partners.org



**Figure 1.** Patterns of distal articular shear injury. Type I: capitellum fracture; Type II: coronal shear fracture; Type III: coronal shear plus lateral epicondyle; Type IV: coronal shear plus lateral epicondyle with impaction of posterolateral column; Type V: Type IV with posterior trochlear fragment; Type IV: Type V with extension to include medial epicondyle.



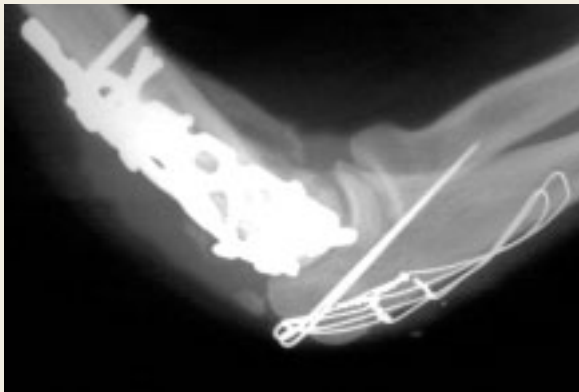**Figure 2.** 3-D reconstruction of computed tomography scan of distal humeral fracture with subtraction of both the radius and the ulna.

## OPERATIVE TREATMENT

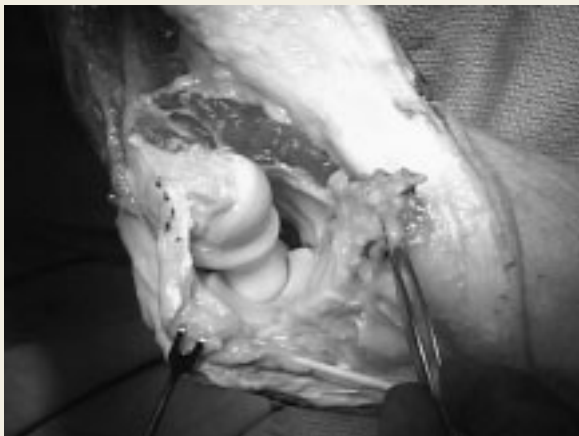
Contemporary issues regarding operative treatment include preoperative planning, surgical exposures, methods of internal fixation, management of the ulnar nerve, and indications for primary total elbow arthroplasty.

### PREOPERATIVE PLANNING

It is well recognized that articular fractures of the distal humerus are not well visualized with standard radiographs. Three-dimensional reconstructions of computed tomography scans have provided a major advance in the radiographic analysis of these injuries. We now use these routinely, particularly



**Figure 3.** Lateral view of elbow illustrating repair technique utilized after olecranon osteotomy.



**Figure 4.** Intraoperative photo illustrating technique of extended lateral exposure for distal articular shear fractures. Exposure to the articular surface is gained by hinging the elbow joint open after reflecting a fractured or osteotomized lateral epicondyle.

with images of the ulna and radius digitally subtracted. Three-dimensional reconstruction also permits visualization of the fracture pattern from multiple vantage points, as the image can be rotated about a central axis in coronal, sagittal and axial planes (Figure 2.).

### SURGICAL EXPOSURES

Concern regarding the potential complications of olecranon osteotomy has stimulated some authors to recommend triceps-splitting approaches, such as that described by<sup>8</sup> Campbell, or triceps-reflecting approaches, such as those described by Bryan and Morrey<sup>9</sup> and O'Driscoll.<sup>10</sup>

We have utilized the olecranon osteotomy for a number of years and have found that with attention to certain details, superb exposure of the distal humerus is possible with few complications. Chevron osteotomy with a thin blade in the midsubstance of the olecranon, reapproximation with obliquely placed Kirschner wires carefully bent in a 90-90 shape and driven into the proximal ulna, and double loops of thin stainless steel tension-band wires will minimize most of the reported complications. Presented at the American Society of Surgery of the Hand in 2001, our experience with 45 consecutive osteotomies resulted in no cases of olecranon nonunion. Hardware removal needed in only six patients (Figure 3.).<sup>11</sup>

We have also developed an extended lateral approach that provides outstanding exposure to the majority of articular shearing fractures.<sup>3</sup> By elevating the lateral head of the triceps and reflecting a fractured or osteotomized lateral epicondyle proximally, the elbow can be hinged open providing nearly full exposure of the distal articular segment (Figure 4.).

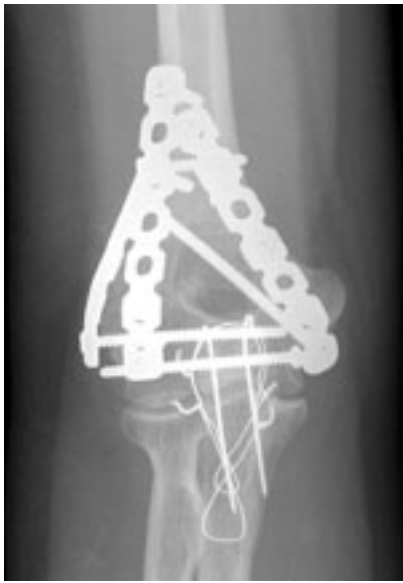### THE ULNAR NERVE

We have long recognized the importance of the ulnar nerve in the outcome of operatively repaired distal humerus fractures.<sup>12-14</sup> Careful exposure and mobilization of the nerve at least 6 centimeters proximal and distal to the cubital tunnel, resection of the distal, medial intermuscular septum, and splitting of the flexor carpi ulnaris head minimize the potential for local fibrosis and resultant compressive neuropathy. Early postoperative ulnar neuritis and pain can result in precipitous loss of motion. If recognized early, surgical decompression can restore a functional outcome.<sup>15</sup>

### INTERNAL FIXATION

Internal fixation of fractures of the distal humerus has traditionally consisted of plate and screws placed along the skeletal columns at different angles to each other. Previously, we suggested that additional fixation could be achieved with addition of even a third plate (Figure 5.).<sup>13</sup>

The advent of plates incorporating screws with threaded heads that "lock" into the holes of the plate has added a new dimension to fixation in osteopenic bone. We are currently part of task force to create a set of implants that are pre-contoured, offer locking screws, and come in a variety of shapes to accommodate the skeletal columns of the distal humerus (Figure 6.). This concept of anatomic pre-contouring has been shown to have useful application with similar implants developed by O'Driscoll at the Mayo Clinic.



**Figure 5.** Post-operative radiograph illustrating use of a third plate for additional stability in cases of complex fractures, particularly those occurring through osteoporotic bone.

### TOTAL ELBOW ARTHROPLASTY

In cases of highly comminuted articular fractures in a low-demand, osteoporotic elderly patients or fractures occurring in elbow with pre-existing inflammatory joint destruction, the experienced surgeon may decide that the distal humerus is not reconstructable. Total elbow arthroplasty (TEA) using a semi-constrained prosthesis has been shown in several studies to be effective primary treatment, at least in the short term.<sup>25,26,27</sup>

The disadvantages of total elbow arthroplasty for acute fractures include the functional restrictions imposed upon the patient, the risk of serious complications such as infection, and the potential for failure of prosthetic articulations with the possible need for revision. We use infirmity and activity level rather than age when considering total elbow arthroplasty for fracture treatment. Our service has been part of a multicenter trial of a new total elbow prosthesis designed by Hastings and Graham.

### COMPLICATIONS

#### STIFFNESS

Loss of motion is common after fractures of the distal humerus. Elbow capsulectomy can often restore motion. We recently reviewed the senior author's (JBJ) experience with elbow capsulectomy for post-traumatic elbow stiffness. One-fifth of the patients required a second procedure, but motion was improved in most patients. Final function and upper extremity-specific health status were related to ongoing dysfunction of the ulnar nerve and to secondary gain, but not to elbow motion or arthrosis.<sup>16</sup>

We have also reviewed the senior author's (JBJ) experience in the release of total bony ankylosis of the elbow after trauma or severe burns. In both situations, the majority of elbows regained functional motion; however, there were several elbows in each

group with recurrent contracture and limited motion despite several surgical procedures. There were no major complications in spite of the complexity and risk of the surgery.<sup>17</sup>

#### ULNAR NEUROPATHY


Ulnar neuropathy is an important source of problems after elbow trauma, and particularly after fractures of the distal humerus. The ulnar nerve can be damaged at the time of the original injury or during surgical treatment. Nerve compression can occur in relation to swelling, scarring, implants, heterotopic bone, or arthrosis. Ulnar neuropathy can cause weakness and numbness, and it may be an important contributor to stiffness and pain. One should pay particular attention to the ulnar nerve in the post-operative management of distal humerus fractures. McKee et al.<sup>14</sup> showed that neurolysis and transposition in patients with ulnar neuropathy following operative treatment of distal humerus fractures can result in significant relief in symptoms and improvement in function.

#### NONUNION

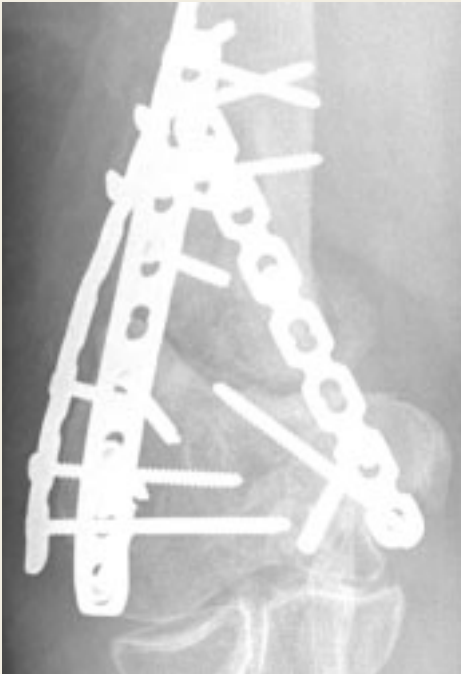
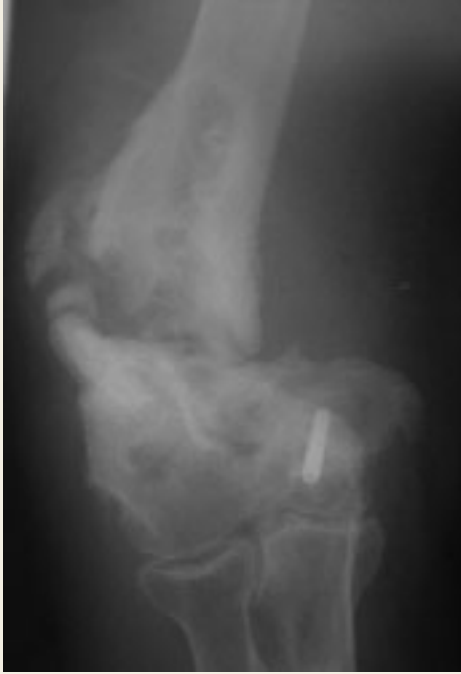Nonunion of the distal humerus after open reduction and internal fixation (ORIF) is a rare complication with an incidence ranging from 2% to 10%. It is seen most commonly in the supracondylar region.<sup>18</sup> Nonunion can be devastating, leading to a painful, flail extremity. In low-demand, elderly individuals with poor or severely deficient bone stock, total elbow arthroplasty represents a reasonable salvage option.<sup>19</sup>

Morrey and Adams<sup>20</sup> reviewed the results of a series of thirty-six distal humeral nonunions treated with total elbow arthroplasty using the Coonrad-Morrey semiconstrained prosthesis. With a mean age of 68 years and mean follow-up of 50.4 months, the authors reported 86% excellent or good results and an average arc of motion from 16° to 127° degrees. Five out of the thirty-six were flail elbows, and all of these were stable at the time of last follow-up. Seven patients (18%) experienced serious complications, including deep infection, particulate synovitis and ulnar nerve palsy.

Two recent series by Helfet and Rosen<sup>21</sup> and Jupiter<sup>22</sup>, however, demonstrate that treatment of distal humeral delayed unions and nonunions with revision ORIF can be expected to have a high rate of success as long as the surgeon adheres to



**Figure 6A-C.** New generation of locking, pre-contoured plates for fractures of the distal humerus.



**Figure 7.** Function can be restored to an elbow with complex nonunion of the distal humerus associated with flail instability of the elbow (A) using stable internal fixation, capsular release, and autogenous bone grafting (B).

certain basic principles. First, revision ORIF must include complete mobilization of the affected joint. This requires meticulous release of all soft tissue contractures limiting elbow motion such that undue stress is not placed upon the fixation construct during post-operative rehabilitation. The importance of complete soft tissue release cannot be overemphasized. Second, one must provide stable fixation at the fracture site. As discussed earlier, a variety of plate constructs can be used to achieve this common goal, but the fixation must be secure enough to permit early post-operative motion. Third, the surgeon should make ample use of autogenous bone grafting in order to optimize the biologic milieu for osteosynthesis. Finally, the ulnar nerve should be routinely transposed and if previously transposed, should undergo neurolysis to prevent post-operative neuropathy.

Helfet et al.<sup>21</sup> reported on a series of 52 patients with delayed unions or nonunions of the distal humerus, ages 16 to 88 years, who underwent revision ORIF. A union rate of 98% was observed, with a 29% incidence of reoperation. The most commonly encountered indication for reoperation was painful hardware. Autologous bone grafting was used in 46 of 52 cases.

In Jupiter's series of 40 patients, the nonunion rate was 10% and good functional results were obtained in most patients. In a subset of 15 very complex patients with flail elbows, 12 patients went on to radiographic union (Figure 7). Among the twelve patients who healed, five (42%) underwent a second operation, the most common indication for which was soft tissue contracture.<sup>22</sup>

Even in very complex nonunions, the native elbow can usually be preserved. Total elbow arthroplasty is used in low-demand, infirm patients and as a salvage procedure for ultimately unsuccessful attempts to gain union.

#### **SUMMARY**

Intraarticular fractures of the distal humerus in adults present a challenging situation to the treating surgeon. The elbow is vital as fulcrum for positioning the hand in space and functionally does not tolerate loss of motion or instability. Anatomic reduction of the distal humeral articular surface, followed by stable fixation to the diaphysis, offers patients the best chance at return to independent function.



## References

1. **Palvanen, M.; Kannus, P.; Niemi, S. and Parkkari, J.:** Secular trends in the osteoporotic fractures of the distal humerus in elderly women. *Eur J Epidem*, 14: 159-64, 1998.
2. **Pajarinen, J and Bjorkenheim, JM:** Operative treatment of Type C intercondylar fractures of the distal humerus: results after a mean follow-up of two years in a series of 18 patients. *J Shoulder Elbow Surg*, 11(1): 48-52, 2002.
3. **Ring, D.; Jupiter, J.B. and Gulotta, L.:** Articular fractures of the distal part of the humerus. *J Bone Joint Surg*, 85-A(2): 232-238, 2003.
4. **McKee, M.D.; Jupiter, J.B. and Bamberger, H.B.:** Coronal shear fractures of the distal end of the humerus. *J Bone Joint Surg*, 78-A(1): 49-54, 1996.
5. **Muller, M.** *The comprehensive classification of fractures of long bones.* Berlin: Springer-Verlag, 1990.
6. **Browner, B; Jupiter, JB, Levine, AM and Trafton, PG, eds.** *Skeletal Trauma*, 3<sup>rd</sup> Ed., Philadelphia, Saunders, 2003.
7. **Jupiter JB, Barnes KA, Goodman LJ, et al.:** Multiplane fractures of the distal humerus. *J Orthop Trauma*, 7(3):216-220, 1993.
8. **Campbell, WC:** Incision for exposure of the elbow joint. *Am J Surg*, 15: 65-67, 1932.
9. **Bryan, R.S. and Morrey, B.F.:** Extensive posterior exposure of the elbow. *Clin Orthop*, 166: 188-192, 1982.
10. **O'Driscoll, S.W.:** The triceps-reflecting anconeus pedicle (TRAP) approach for distal humeral fractures and nonunions. *Orthop Clin North Am*, 31(1): 91-101.
11. **Ring, D; Gulotta, L; Chin, K and Jupiter, JB:** Technical tricks: Olecranon osteotomy for exposure of fractures and nonunions of the distal humerus. Presented at the 56<sup>th</sup> Annual Meeting of the American Society for Surgery of the Hand. Baltimore, MD, 2001.
12. **Ring, D. and Jupiter, J.:** Fractures of the distal humerus. *Orthop Clin N Am*, 31(1): 103-113, 2000.
13. **Jupiter, JB and Goodman, LJ:** The management of complex distal humerus nonunion in the elderly by elbow capsulectomy, triple plating, and ulnar nerve neurolysis. *J Shoulder Elbow Surg*, 1:37, 1992.
14. **McKee, MD; Jupiter, JB; Bosse, G and Goodman, L.:** Outcome of ulnar neurolysis during post-traumatic reconstruction of the elbow. *J Bone Joint Surg*, 80-B(1): 100-105, 1998.
15. **Faierman, E; Wang, J and Jupiter, JB:** Secondary ulnar nerve palsy in adults after elbow trauma: a report of two cases. *J Hand Surg*, 26(4): 675-678, 2001.
16. **Ring D, Jupiter JB, Kipps A, Roy AK, Gulotta L.** Health status after elbow contracture release. Presented at the 55<sup>th</sup> Annual Meeting of the American Society for Surgery of the Hand. Seattle, WA; October 5-7, 2000.
17. **Ring D, Jupiter JB.** The operative release of bony elbow ankylosis: The results are better after trauma than after severe burns. Presented at the 15<sup>th</sup> Annual Open Meeting of the American Shoulder and Elbow Surgeons. Anaheim, California. February 7, 1999.
18. **Ray, P.S.; Kakarlapudi, K.; Rajsekhar, C. and Bhamra, M.S.:** Total elbow arthroplasty as primary treatment for distal humeral fractures in elderly patients. *Injury*, 31: 687-692, 2000.
19. **Ramsey, M.L.; Adams, R.A. and Morrey, B.F.:** Instability of the elbow treated with semiconstrained total elbow arthroplasty. *J Bone Joint Surg*, 81-A(1): 38-47, 1999.
20. **Morrey, BF and Adams, RA:** Semiconstrained elbow replacement for distal humeral nonunion. *J Bone Joint Surg*, 77-B: 67-72, 1995.
21. **Helfet, D.L.; Kloen, P; Anand, N. and Rosen, H.S.:** Open reduction and internal fixation of delayed unions and nonunions of fractures of the distal part of the humerus. *J Bone Joint Surg*, 85-A(1): 33-40, 2003.
22. **Ring D, Jupiter JB, Gulotta L.** Ununited fractures of the distal humerus: plate fixation and autogenous bone graft. Presented at the 69<sup>th</sup> Annual Meeting of the American Academy of Orthopaedic Surgeons, Dallas, Texas. February 15, 2002.