

# Intra-Articular Anesthetic Injection of the Hip for Confirmation of Symptomatic Tears of the Acetabular Labrum: A Systematic Review

## ABSTRACT

**BACKGROUND** The purpose of this study was to review the evidence on diagnostic intra-articular anesthetic injections of the hip for confirmation of symptomatic injury to the acetabular labrum among hip arthroscopy candidates.

**METHODS** Broad search terms were used to identify relevant English literature in Pubmed, MEDLINE and CINAHL databases. Studies on diagnostic injection of the hip and intra-articular injections were included.

**RESULTS** A total of 1,172 original citations were identified and, of these, 6 (0.5%) met inclusion and exclusion criteria after full text review. Half of these studies were level IV evidence. All injections were administered under fluoroscopic guidance. Bupivacaine was the most commonly used intra-articular anesthetic. 85.8% of patients were identified as “positive” responders although the defining parameters of a “positive” response varied amongst the studies. No study analyzed the subjects who did not experience relief of pain or reported worse pain after intra-articular injection (IAI). No study reported the diagnostic sensitivity, specificity, negative predictive or positive predictive values for IAI in confirming symptomatic intra-articular pathology.

**CONCLUSION** Not every patient with a tear of the acetabular labrum experiences pain relief after diagnostic IAI. More women than men undergo IAI. Due to inconsistent reporting and lack of standardization in the methodologies for assessing the degree and significance of response to IAI, it is unclear if diagnostic IAI confirms symptomatic labral injury or non-specific intra-articular injury. Well-designed studies are needed to determine the clinical significance of pain relief after IAI among patients considered to be candidates for hip arthroscopy.

Symptomatic labral tears of the hip are most frequently seen in the setting of femoroacetabular impingement (FAI), a condition characterized by repetitive abnormal contact between the acetabulum and femoral neck resulting in progressive damage to the labrum, adjacent articular cartilage, and ultimately premature development of osteoarthritis.<sup>1,2</sup> Surgical management of symptomatic labral tears and associated impingement has led to improved functional outcomes and reduced pain.<sup>3,4</sup> However, the efficacy of surgical management is contingent upon an accurate diagnosis. This can be difficult given that there is no pathognomonic finding for this condition and several methods used to diagnose symptomatic labral tears have been cited as unreliable or currently lack substantial evidence-based support.<sup>5,6,7</sup>

Kyle Alpaugh, MD<sup>1</sup>  
Catherine Logan, MD<sup>2</sup>  
Shivam Upadhyaya, MD<sup>3</sup>  
Scott D. Martin, MD<sup>4</sup>

## AUTHOR AFFILIATIONS

<sup>1</sup>Department of Orthopedic Surgery,  
University of Massachusetts Memorial  
Medical Center, Worcester, MA

<sup>2</sup>Harvard Combined Orthopedic Surgery  
Residency Program, Boston, MA

<sup>3</sup>Department of Orthopedic Surgery,  
Brigham & Women's Hospital, Boston, MA

## CORRESPONDING AUTHOR

Kyle Alpaugh, M.D.  
55 Lake Avenue North  
Worcester, MA 01655  
Phone: 508-334-1000  
Fax: 617-732-9263  
[Kyle.Alpaugh@umassmemorial.org](mailto:Kyle.Alpaugh@umassmemorial.org)

The authors report no conflict of interest related to this work.

©2016 by The Orthopaedic Journal at  
Harvard Medical School

First described by Kleiner et al., intra-articular anesthetic injections (IAI) have been traditionally used to localize and differentiate pain caused by osteoarthritis (OA) of the hip.<sup>8-14</sup> Although IAI has minimal proven therapeutic benefit, immediate and significant pain relief appears to localize intra-articular pain generators to within the hip among patients harboring osteoarthritis.<sup>10,12</sup> However, a recent meta-analysis of the literature on this subject concluded that no recommendation could be made regarding the role of diagnostic IAI for OA in clinical practice.<sup>15</sup>

Similarly, emphasis has been placed on pain relief after diagnostic IAI to corroborate presumptive labral injury.<sup>16-21</sup> Among asymptomatic individuals, labral tears and osseous morphology that can be classified as pathologic have been noted to be common.<sup>22-24</sup> Therefore, a simple diagnostic test that can be used to differentiate symptomatic labral injury from other causes of hip pain would be useful.

Many orthopedic surgeons adjunctively use the response, or degree of pain relief following diagnostic intra-articular anesthetic injection (IAI) of the hip, to confirm clinical suspicion of symptomatic labral tear, particularly in the setting of FAI.<sup>5,6</sup> Despite the potential benefit of IAI for confirmation of symptomatic labral pathology amenable to arthroscopic intervention, there has been no formal review of the evidence that exists on this practice. The purpose of this study was to review the evidence on diagnostic intra-articular anesthetic injections of the hip for confirmation of symptomatic injury to the acetabular labrum among hip arthroscopy candidates. We hypothesize that patients with symptomatic labral injury do not experience pain relief after diagnostic IAI of the hip.

**METHODS**

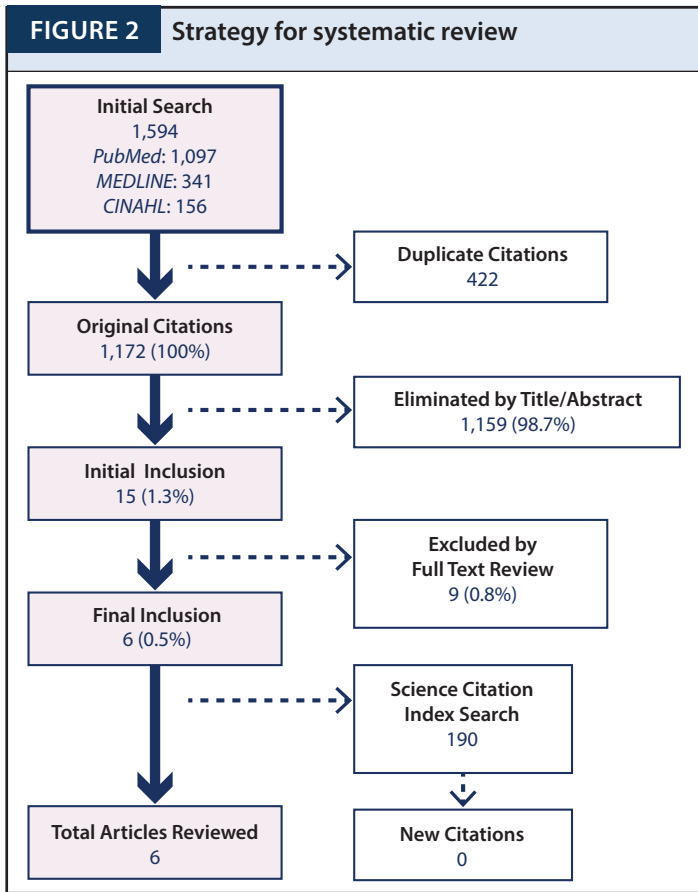
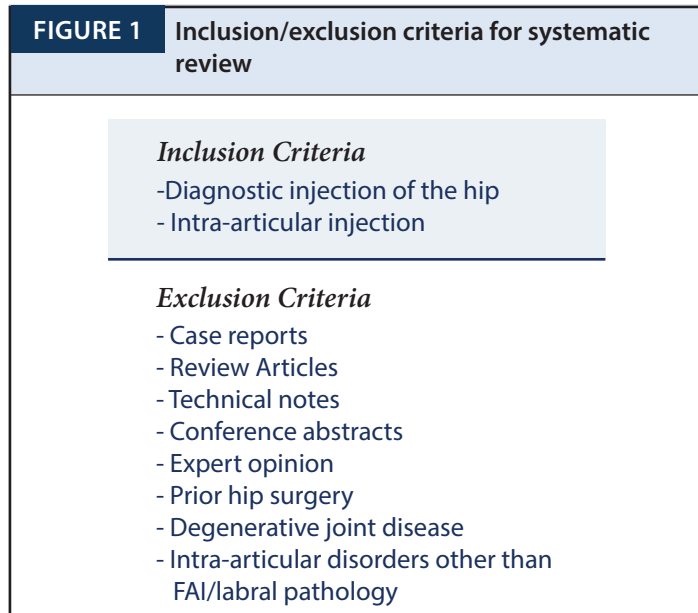
**Search Strategy**

The electronic databases of PubMed, OVID MEDLINE (1946-present with weekly updates as well as In-Process & Other Non-Indexed Citations), and Cumulative Index of Nursing and Allied Health Literature (CINAHL) were searched in entirety up until the search date of February 12, 2015. The search terms “hip”, “injection”, “diagnosis”, “intra-articular” and “anesthetic” were used for the development of search phrases. Details regarding the search phrases utilized during the search process of this study can be found in **Appendix 1\***. Search results were limited to those published in English and studies only involving human subjects.

**Search Results, Study Selection, and Systematic Elimination**

The search process returned 1,097 results from PubMed, 341 results from MEDLINE and 156 results from CINAHL. Of the 1,594 total citations, 422 were found to be redundant and eliminated. There were 1,172 original citations. Using inclusion and exclusion criteria (**Figure 1**), 15 citations were identified as relevant based on the review of the title and abstract. Full-text review eliminated another 9 citations leaving 6 citations eligible for study inclusion. Reasons for exclusion were technique papers (6), therapeutic IAI (1), hip dysplasia (1) and unrelated to FAI (1). The 162 references of these 6 eligible citations were searched for additional non-redundant citations eligible for inclusion; no additional citations were identified. In addition, the 6 eligible citations were

cross-referenced in the Web of Science Citation Index as references in other studies that may have been eligible for review but missed in the original search process. All studies were indexed allowing them to be searched. These studies have been cited on 190 occasions at the time of this review. No additional studies were deemed eligible for inclusion. In total, 6 studies were included in this systematic review (**Figure 2**).<sup>16-21</sup>



## Data Extraction

Data points were chosen, after agreement by all authors, for extraction based on relevance to the needs of the study. Data points of choice were general study characteristics including demographic information such as subject age and sex, information on subject assessment with recommended screening tests during physical examination including impingement testing or flexion internal rotation testing,<sup>7</sup> imaging studies including plain radiography and magnetic resonance imaging (MRI) or arthrography (MRA), methodological data including route of IAI administration, injection composition and timeline for IAI response assessment. The level of evidence was reported as defined by Wright et al.<sup>25</sup>

The purpose, inclusion and exclusion criteria, pain provocation maneuvers, definition of a “positive” response to IAI, number of “positive” responses, and conclusion was summarized from each study, when available. Specific information on the utility of diagnostic IAI was searched for and included sensitivity, specificity, positive predictive value, negative predictive value and accuracy, when reported. In addition, information on the correlation of symptoms, pertinent physical examination findings, pre-operative imaging study results, and pathology identified intra-operatively were noted.

## Data Synthesis

The information abstracted from the included citations did not permit for a higher level of analysis due to heterogeneity of data. Frequency weight means were assigned to subject age. The more subjects evaluated in a study, the greater the weight that was assigned to that value. If a missing value was encountered, it was excluded from weighted mean and range calculations. The remainder of statistical analysis was descriptive.

## RESULTS

### Study Characteristics

Of the 6 studies included in this review, 3 (50%) were level IV evidence, 2 (33%) level III and 1 (17%) level II evidence. Four studies (67%) took place in the United States. A total of 332 subjects were available for review. The weighted mean age of this cohort was 36.1 years (range, 29.9-42 years) with one study not reporting subject age. Four studies reported the sex ratio of their respective cohorts; 62.2% (140 of 225) of the subjects were female. Five studies (83%) specifically reported the use of physical examination to screen subjects for FAI/labral tears and all of these studies employed the use of either the impingement test or flexion-internal rotation test (**Table 1**).

Study (Yr-Country)	Study Design (LOE)	Sample Size (Female:Male)	Mean Age, Range	Screening Physical Exam Tests	Imaging		Diagnostic Intra-articular Injection	
					Radiographic Osteoarthritis	MRA/MRI	Administration/Content/Volume	Post-Injection Pain Assessment
<i>Arnold et al.</i> (2011-US)	Retrospective case series (IV)	52 (32F:20M)	37, 15-68 yrs	Yes	NR	MRA	Fluoroscopic guided 5 mL saline 5 mL iodinated contrast 5 mL 0.5% ropivacaine HCL 5 mL 1% preservative-free lidocaine 0.1 mL gadolinium Total volume: 12-15 ml	10-30 minutes
<i>Ayeni et al.</i> (2014-Canada)	Prospective case series (II)	52 (30F:22M)	37, 16-62 yrs	Yes	NR	MRI	Fluoroscopic guided 5 mL 0.25 % bupivacaine 40 mg methylprednisolone acetate Total volume: 10 mL maximum	Daily for 2 weeks
<i>Bryd &amp; Jones</i> (2004-US)	Retrospective case series (III)	40 (NR)	NR	Yes	NR	MRA	Fluoroscopic guided 0.05 mL gadolinium 3 mL iodinated contrast 6 mL 0.5% bupivacaine Total volume: 9 ml maximum	NR
<i>Kivlan et al.</i> (2012-US)	Retrospective case series (IV)	72 (54F:18M)	29.9, 16-55 yrs	Yes	KL 0-2	MRA	Fluoroscopic guided 6 ml 1% lidocaine 6 mL 0.25% bupivacaine 80 mg triamcinolone Total volume: 14 ml maximum	2 hours
<i>Martin et al.</i> (2008-US)	Prospective case series (III)	49 (24F:25M)	42, 18-68 yrs	Yes	None (11), Minimal (17), Mild (10), Moderate (8), Advanced (2)	MRA	Fluoroscopic guided 6 ml 1% lidocaine 6 mL 0.25% bupivacaine 80 mg triamcinolone Total volume: 14 ml maximum	2 hours
<i>Mathews et al.</i> (2014-Eng.) [Letter to Ed.]	Retrospective case series (IV)	67 (NR)	37 (NR)	NR	NR	MRI	Fluoroscopic guided 10 mL 0.25% levobupivacaine Total volume: 10 mL maximum	Immediate and Late (not defined)

NR=not reported; MRA= magnetic resonance arthrography; MRI=magnetic resonance imaging, ml=milliliters

**TABLE 2** Selected correlations made with diagnostic IAI by citation

Study (Year)	Correlation of Diagnostic IAI with the following			
	Symptoms/Physical Examination	Pre-Operative Imaging	Arthroscopic Findings	Post-Operative Outcome
<i>Arnold et al.</i> (2011)	Yes	No	No	No
<i>Ayeni et al.</i> (2014)	No	No	No	Yes
<i>Byrd &amp; Jones.</i> (2004)	No	No	Yes	No
<i>Kivlan et al.</i> (2012)	No	No	Yes	No
<i>Martin et al.</i> (2008)	Yes	Yes	No	No
<i>Mathews et al.</i> (2014)	No	No	Yes	No

Five studies used screening radiographs as part of the evaluation process, although the presence and degree of radiographic arthritis was reported by only 2 (33%) of the studies. MRI was used to confirm intra-articular pathology in all studies. Use of arthrography was common with MRA cited in 4 of 6 (66%) studies. The two studies employing MRI without contrast enhancement were based in Canada and England, suggesting regional variation in the diagnostic evaluation of labral pathology. Irrespective of geographic location, all studies (100%) employed fluoroscopic guidance to administer diagnostic IAI of the hip with or without subsequent arthrography. Bupivacaine was the most commonly used local anesthetic (4 of 6 studies), and 3 studies added steroid to the injection solution with triamcinolone as the most common addition. Reported volumes of injectate ranged from 9-15 milliliters.

The method for assessing the degree of pain relief, indicating whether or not a “positive” response was achieved, varied among studies in this review (Table 2). Only one study required a “positive” response to be included in their analysis. Across all studies, the percentage of “positive” responses to pain varied from 55-100%. Overall, 85.8% (285/332) reported a “positive” response; however, the definition of a “positive” response varied according to each study. No study identified complications, adverse events or analyzed subjects who had no pain relief or worse pain after IAI.

The purpose of the included studies was to associate the response of IAI to symptoms and physical examination in 2 studies, the findings of arthrography in 1 study, the intra-articular pathology seen during arthroscopy in 3 studies, and the post-operative outcomes in 1 study (Tables 2 & 3). No studies reported the diagnostic sensitivity, specificity, negative predictive or positive predictive values for IAI in confirming symptomatic intra-articular pathology. No studies were dedicated to reporting the response to diagnostic IAI in children or adolescents.

## DISCUSSION

Emphasis has been placed on how the response to diagnostic IAI correlates with symptoms, physical examination, imaging findings, intra-operative pathology and post-operative outcomes. This review identified that not every patient with evidence of a symptomatic labral tear experiences pain relief after

diagnostic IAI of the hip. However, the majority of patients experienced at least some degree of pain relief following this test. Unfortunately, there were patients who did not experience pain relief despite clinical, radiographic and intra-operative evidence of acetabular labrum injury.<sup>19,20</sup> These results imply that IAI can aid in confirming a diagnosis of symptomatic labral injury but is not 100% reliable. Furthermore, it raises questions as to why patients with identifiable labral pathology and hip pain would not respond favorably to IAI.

Individuals harboring symptomatic labral pathology historically are young adults with activity-limiting groin pain. The mean age of the cohort in this review is older than that reported by a large, multicenter epidemiologic study on patients undergoing hip arthroscopy in North America.<sup>26</sup> This may indicate that IAI is used more frequently among older patients in whom other reasons for hip pain, such as osteoarthritis or referred pain from disorders of the lumbar spine, may exist. Irrespective of age, clinical examination and plain radiography of these patients frequently non-specific.<sup>27</sup> Many cite multiple symptoms, respond variably to physical examination and present with disparate radiographic abnormalities as well as intra-operative pathology according to sex.<sup>27,28</sup>

The majority of patients represented in this review were women. It is plausible that women, due to more subtle radiographic findings of impingement and preserved range of motion on physical exam, are more likely to undergo diagnostic IAI for confirmation of a suspected labral injury.<sup>28,29</sup> Despite similar levels of pain, women tend to report greater functional disability and have less severe injury seen during arthroscopy, which may explain why women seem to undergo diagnostic IAI more often than men.<sup>28,29</sup>

It does not appear that symptomatology, results of physical examination or the presence of FAI predict the response to diagnostic IAI but the presence of labral or chondral injury may be influential.<sup>16-21</sup> The severity of radiographic osteoarthritis has been positively correlated with relief from IAI,<sup>10</sup> suggesting that the stage of disease may play a role in the overall degree of response to anesthetic injection. Martin and colleagues found no difference in pain relief between possible and definite tears of the labrum identified by arthrography.<sup>19</sup> However, it should be noted that 20% of this cohort consisted of patients with moderate to severe radiographic osteoarthritis. In this setting, pain from osteoarthritis may obscure relief from pain attributable to

TABLE 3

Purpose, eligibility criteria of subjects, definition &amp; evaluation of response to intra-articular injection &amp; conclusions reached by reviewed citations



Study (Yr)	Purpose	Inclusion/Exclusion Criteria
Arnold et al. (2011)	Use FGIA injections combined with hip arthroscopy to determine hip pain referral patterns of patients with labral tears, and to evaluate a new pain "circle" diagram	<p><b>Inclusion</b></p> <ul style="list-style-type: none"> <li>• preoperative FGIA anesthetic hip joint injection</li> <li>• completed PCD and a visual analog pain scale pre- and post injection</li> <li>• significant (<math>\geq 80\%</math>) pain relief</li> </ul> <p>hip arthroscopy that documented a labral tear and minimal (<math>\leq</math> grade II Outer-bridge) articular cartilage damage</p> <p><b>Exclusion</b></p> <ul style="list-style-type: none"> <li>• patients experiencing no pain relief from the FGIA anesthetic injection</li> <li>• grade III or IV degenerative articular changes found at hip arthroscopy</li> <li>• had undergone prior hip surgery</li> </ul>
Ayeni et al. (2014)	Document ability of a diagnostic hip injection to predict short-term functional outcomes following arthroscopic surgical management of FAI	<p><b>Inclusion</b></p> <ul style="list-style-type: none"> <li>• patients diagnosed with FAI had intra-articular hip injection prior to surgery</li> </ul> <p><b>Exclusion</b></p> <ul style="list-style-type: none"> <li>• previous hip surgery</li> <li>• pediatric hip disease</li> <li>• previous hip trauma</li> <li>• chronic pain</li> <li>• ongoing litigation/compensation claims related to a hip condition</li> </ul>
Bryd & Jones (2004)	Correlate diagnostic accuracy of clinical assessment, MRI, MRA, and intra-articular injection with arthroscopic findings of patients who have had these evaluations	<p><b>Inclusion</b></p> <ul style="list-style-type: none"> <li>• patients referred for hip arthroscopy received intra-articular anesthetic injection</li> </ul> <p><b>Exclusion</b></p> <ul style="list-style-type: none"> <li>• patients who did not undergo MRA and anesthetic injection</li> </ul>
Kivlan et al. (2012)	Compare the percent relief from IAI among subjects with arthroscopic findings of (FAI) and labral and chondral pathologies - controlling for coexisting extra-articular pathology	<p><b>Inclusion</b></p> <ul style="list-style-type: none"> <li>• consecutive surgical patients who reported their percent relief from injection within 2 hours of injection and had arthroscopic surgery of the hip consented to participate in the study</li> </ul> <p><b>Exclusion</b></p> <ul style="list-style-type: none"> <li>• did not report pain relief in 2 hour window</li> <li>• non-English speakers</li> </ul>
Martin et al. (2008)	Quantify amount of pain reduction after an intra-articular injection in those with a definite tear, a possible tear, or no labral tear	<p><b>Inclusion</b></p> <ul style="list-style-type: none"> <li>• primary complaint of hip pain in anterior, posterior, lateral, and/or groin regions</li> </ul> <p><b>Exclusion</b></p> <ul style="list-style-type: none"> <li>• &lt;18 years</li> <li>• , not being able to speak or understand English</li> <li>• having the primary area of pain located in an area other than the hip region (i.e., lumbar spine)</li> </ul>
Mathews et al. (2014) [Letter to Editor]	Correlate a positive response to IAI with intra-articular pathology	<p><b>Inclusion</b></p> <ul style="list-style-type: none"> <li>• NR</li> </ul> <p><b>Exclusion</b></p> <ul style="list-style-type: none"> <li>• NR</li> </ul>

FGIA=fluoroscopically guided intra-articular injection; FAI=femoroacetabular impingement; PCD=pain circle diagram; NR=not reported; MRA=magnetic resonance arthrography; MRI=magnetic resonance imaging; IAI=intra-articular anesthetic injection

labral pathology. Therefore, the use of IAI to diagnose symptomatic labral pathology in patients with considerable, radiographic arthritic burden may be of little use.

Several authors have associated pain relief occurring after diagnostic IAI with intra-articular pathology identified at the time of arthroscopy.<sup>18,20,21</sup> Byrd and Jones were the first to report that pronounced transient relief of hip-related symptoms after IAI

was 90% accurate in identifying an intra-articular abnormality, demonstrating the potential clinical utility of this test.<sup>18</sup> To that end, Kivlan et al. sought to determine if extra-articular pathology significantly affected patient-reported responses to IAI in patients with arthroscopically proven FAI.<sup>21</sup> It was found that extra-articular pathology did not significantly influence degree of pain relief and that patients with any degree of chondral damage experienced

TABLE 3 (continued)

Hip Pain Provocation	Definition of Positive Response	Positive Responders	Conclusion
Performance of subjective activities that recreate hip symptoms before and after injection	Significant (>80%) pain reduction 10-30 minutes after diagnostic injection in $\geq 1$ "circle" areas	100% • all subjects in study had positive response as inclusion criteria	The most common locations of pain were the central groin and lateral peritrochanteric area. The least common were the ischial tuberosity and the anterior thigh, which are 2 areas often associated with osteoarthritis of the hip. The use of PCD combined with FGIA anesthetic injection may help physicians reconcile the expectations of those patients with labral tears who believe that hip arthroscopy will treat their multiple areas of pain.
Performance of subjective activities that recreate hip symptoms before and after injection on a daily basis for 2 weeks following injection	Pain diary for 2 weeks to document pain response categorically • none, partial, or complete	42/52 (81%) • partial and complete relief	A positive response from an intra-articular hip injection is not a strong predictor of short-term functional outcomes following arthroscopic management of FAI. However, a negative response from an intra-articular hip injection may predict a higher likelihood of having a negative result from surgery.
Performance of subjective activities that recreate hip symptoms before and after injection	Pronounced temporary improvement in symptoms • negative response if no improvement noted or if improvement equivocal	37/40 (92.5%)	Clinical assessment accurately determined the existence of intra-articular abnormality but was poor at defining its nature. Magnetic resonance arthrography was much more sensitive than magnetic resonance imaging at detecting various lesions but had twice as many false-positive interpretations. Response to an intra-articular injection of anesthetic was a 90% reliable indicator of intra-articular abnormality.
Performance of subjective activities that recreate hip symptoms within the first two hours after injection	None • subjective pain relief graded on continuous scale from 0-100%	72/72 (100%)	Subjects with chondral damage had greater relief from injection than those without, regardless of severity. The presence and severity of FAI and labral pathology did not influence the percent relief from injection. Concurrent extra-articular pathology did not alter the interpretation of the percent relief from injection. Therefore the interpretation and diagnostic value of an anesthetic injection in those with primary intra-articular pathology does not need to be altered by the presence of coexisting extra-articular hip pathology.
Performance of activities and getting into positions that in the past consistently aggravated hip pain	>50% relief for analysis • pain relief graded from 0-100% on continuous scale	27/49 (55.1%)	The symptoms and signs investigated in this study did not accurately or consistently identify subjects with primary intra-articular pain sources. Furthermore, candidates for hip arthroscopy with a labral tear identified on MRI arthrogram had varied responses to anesthetic intra-articular injection. Therefore all labral tears identified on MRI arthrogram may not be a major contributor to patients' pain complaints, and medical personnel should look for other causes of pain.
NR	Any degree of pain relief considered positive response	55/67 (82.1%)	Intra-articular findings in patients who did not respond to the diagnostic injection did not differ from those patients who responded to the injection

significantly greater pain relief than those without chondral injury. Further, the severity of FAI and labral abnormalities did not alter the response to IAI. It is interesting to note that among patients with less than 50% improvement of symptoms after injection, the incidence of chondral lesions adjacent to labral pathology was low. Mathews and associates noted labral pathology that was associated with a mean of 2.3 chondrolabral lesions per hip

joint during arthroscopy of the hips that responded to anesthetic injection.<sup>20</sup> The pooled evidence suggests that diagnostic IAI of the hip may confirm an intra-articular pain generator but is non-specific. There are many potential sources of intra-articular pain; this makes it difficult to discern between labral or chondral injury as the primary pain generator especially when the presence of both may have an additive effect on pain. Other potential intra-articu-

lar etiologies of hip pain that may respond favorably to IAI include loose bodies from osteochondromatosis, inflammatory synovitis and synovial tumors including pigmented villonodular synovitis. Extra-articular sources of hip pain that must be accounted for include referred pain from pathology of the lumbar spine or sacroiliac joints, femoral neck stress fractures and soft tissue injuries such as sports hernia and iliopsoas tendonitis. Surgeons should remain cognizant of this and always pair the response to diagnostic IAI with patient history, results of physical exam and imaging findings in order to eliminate or identify confounding sources of hip pain in the setting of suspected labral injury.

A recent investigation by Ayeni et al.<sup>17</sup> looked to determine if the response to pre-operative IAI was predictive of short-term post-arthroscopic outcomes. Finding that not all patients who experienced complete or partial pain relief from IAI had satisfactory (Modified Harris Hip Score >70) outcomes, it was concluded that a positive response to IAI is not a strong predictor of clinical outcomes and that a negative response may predict an unsatisfactory post-surgical outcome. The authors recognized several aspects that limit the application of their findings including small sample size and short duration of follow-up for outcomes.

Prognostic indicators of functional outcomes following hip arthroscopy have received much attention. Recognized predictors of poor outcomes after surgical management of FAI include increasing age, presence of arthritic changes, longer pre-operative symptom duration and lower baseline scores on functional outcome measures.<sup>30</sup> However, future studies on this topic should also report on the relationship between the response to IAI and pre-operative patient characteristics such as joint space narrowing and progressive severity of OA that have been identified as influential in portending worse surgical outcomes among patients undergoing hip arthroscopy.<sup>31,32</sup>

### Strengths & Limitations

The strengths of this review are that we have summarized the literature on an important but poorly understood diagnostic tool for hip arthroscopy candidates. By doing so, our goal is to enable orthopedic surgeons who use diagnostic IAI of the hip to recognize the strengths and weaknesses of this test. We acknowledge the limitations that are inherent to any systematic review. Most of the studies were conducted by high volume hip arthroscopists; introducing selection bias that cannot be accounted for secondary to practices in patient selection and referral patterns. The use of broad search criteria as well as specific inclusion and exclusion criteria help to avoid a selection bias. The overall low quality of evidence and variability of study methodology and reporting prevented higher-level analysis. No studies have taken an in depth look at patients who experience no relief or worse pain after injection. False negative results do occur and post-procedural pain, potentially related to technique, has been reported to be prevalent after arthrography of hip. Further studies are needed to elucidate why and in which patients these responses occur.<sup>18,20,33-35</sup> The information conveyed in this review is not applicable to children and adolescents, consistent with a recent review on outcomes of hip arthroscopy in skeletally immature patients.<sup>36</sup> The few studies

that exist on this topic make it difficult to provide recommendations for proper use of diagnostic IAI in clinical practice.

### CONCLUSION

Not every patient with a tear of the acetabular labrum experiences pain relief after diagnostic IAI. Based on the available studies, more women than men undergo IAI. Due to inconsistent reporting and lack of standardization in the methodologies for assessing the degree and significance of response to IAI, it is unclear if diagnostic IAI confirms symptomatic labral injury or non-specific intra-articular injury. Well-designed studies are needed to determine the clinical significance of pain relief after IAI among patients considered to be candidates for hip arthroscopy.

### \*APPENDIX

Supplementary material available from:

<http://www.orthojournalhms.org/17/supplementaryMaterial.html>

### REFERENCES

1. McCarthy JC, Noble PC, Schuck MR, Wright J, Lee J, Otto E. Aufranc Award: The role of labral lesions to development of early degenerative hip disease. *Clin Orthop Relat Res*. 2001 Dec;(393):25-37.
2. Ganz R, Parvizi J, Beck M, Leunig M, Nötzli H, Siebenrock KA. Femoroacetabular impingement: a cause for osteoarthritis of the hip. *Clin Orthop Relat Res*. 2003 Dec;(417):112-20.
3. Espinosa N, Rothenfluh DA, Beck M, Ganz R, Leunig M. Treatment of femoro-acetabular impingement: preliminary results of labral refixation. *J Bone Joint Surg Am*. 2006 May;88(5):925-35.
4. Philippon MJ, Briggs KK, Yen YM, Kuppersmith DA. Outcomes following hip arthroscopy for femoroacetabular impingement with associated chondrolabral dysfunction: minimum two-year follow-up. *J Bone Joint Surg Br*. 2009 Jan;91(1):16-23. doi: 10.1302/0301-620X.91B1.21329.
5. Nepple JJ, Prather H, Trousdale RT, Clohisy JC, Beaulé PE, Glyn-Jones S, Kim YJ. Clinical diagnosis of femoroacetabular impingement. *J Am Acad Orthop Surg*. 2013;21 Suppl 1:S16-9. doi: 10.5435/JAAOS-21-07-S16.
6. Reiman MP, Thorborg K. Femoroacetabular impingement surgery: are we moving too fast and too far beyond the evidence? *Br J Sports Med*. 2015 Jun;49(12):782-4. doi: 10.1136/bjsports-2014-093821. Epub 2015 Feb 12.

7. Reiman MP, Goode AP, Cook CE, Hölmich P, Thorborg K. Diagnostic accuracy of clinical tests for the diagnosis of hip femoroacetabular impingement/labral tear: a systematic review with meta-analysis. *Br J Sports Med.* 2015 Jun;49(12):811. doi: 10.1136/bjsports-2014-094302. Epub 2014 Dec 16.
8. Kleiner JB, Thorne RP, Curd JG. The value of bupivacaine hip injection in the differentiation of coxarthrosis from lower extremity neuropathy. *J Rheumatol.* 1991 Mar;18(3):422-7.
9. Pateder DB, Hungerford MW. Use of fluoroscopically guided intraarticular hip injection in differentiating the pain source in concomitant hip and lumbar spine arthritis. *Am J Orthop (Belle Mead NJ).* 2007 Nov;36(11):591-3.
10. Deshmukh AJ, Thakur RR, Goyal A, Klein DA, Ranawat AS, Rodriguez JA. Accuracy of diagnostic injection in differentiating source of atypical hip pain. *J Arthroplasty.* 2010 Sep;25(6 Suppl):129-33. doi: 10.1016/j.arth.2010.04.015. Epub 2010 May 31.
11. Illgen RL, 2nd, Honkamp NJ, Weisman MH, Hagenauer ME, Heiner JP, Anderson PA. The diagnostic and predictive value of hip anesthetic arthrograms in selected patients before total hip arthroplasty. *J Arthroplasty.* 2006 Aug;21(5):724-30.
12. Crawford RW, Gie GA, Ling RS, Murray DW. Diagnostic value of intra-articular anaesthetic in primary osteoarthritis of the hip. *J Bone Joint Surg Br.* 1998 Mar;80(2):279-81.
13. Faraj AA, Kumaraguru P, Kosygan K. Intra-articular bupivacaine hip injection in differentiation of coxarthrosis from referred thigh pain: a 10 year study. *Acta Orthop Belg.* 2003 Dec;69(6):518-21.
14. Yoong P, Guirguis R, Darrah R, Wijeratna M, Porteous MJ. Evaluation of ultrasound-guided diagnostic local anaesthetic hip joint injection for osteoarthritis. *Skeletal Radiol.* 2012 Aug;41(8):981-5. doi: 10.1007/s00256-011-1290-4. Epub 2011 Nov 10.
15. Dorleijn DM, Luijsterburg PA, Bierma-Zeinstra SM, Bos PK. Is anesthetic hip joint injection useful in diagnosing hip osteoarthritis? A meta-analysis of case series. *J Arthroplasty.* 2014 Jun;29(6):1236-1242.e1. doi: 10.1016/j.arth.2013.12.008. Epub 2013 Dec 28.
16. Arnold DR, Keene JS, Blankenbaker DG, Desmet AA. Hip pain referral patterns in patients with labral tears: analysis based on intra-articular anesthetic injections, hip arthroscopy, and a new pain "circle" diagram. *Phys Sportsmed.* 2011 Feb;39(1):29-35. doi: 10.3810/psm.2011.02.1859.
17. Ayeni OR, Farrokhyar F, Crouch S, Chan K, Sprague S, Bhandari M. Pre-operative intra-articular hip injection as a predictor of short-term outcome following arthroscopic management of femoroacetabular impingement. *Knee Surg Sports Traumatol Arthrosc.* 2014 Apr;22(4):801-5. doi: 10.1007/s00167-014-2883-y. Epub 2014 Feb 5.
18. Byrd JW, Jones KS. Diagnostic accuracy of clinical assessment, magnetic resonance imaging, magnetic resonance arthrography, and intra-articular injection in hip arthroscopy patients. *Am J Sports Med.* 2004 Oct-Nov;32(7):1668-74.
19. Martin RL, Irrgang JJ, Sekiya JK. The diagnostic accuracy of a clinical examination in determining intra-articular hip pain for potential hip arthroscopy candidates. *Arthroscopy.* 2008 Sep;24(9):1013-8. doi: 10.1016/j.arthro.2008.04.075. Epub 2008 Jun 16.
20. Mathews J, Alshameeri Z, Loveday D, Khanduja V. The role of fluoroscopically guided intra-articular hip injections in potential candidates for hip arthroscopy: experience at a UK tertiary referral center over 34 months. *Arthroscopy.* 2014 Feb;30(2):153-5. doi: 10.1016/j.arthro.2013.11.023.
21. Kivlan BR, Martin RL, Sekiya JK. Response to diagnostic injection in patients with femoroacetabular impingement, labral tears, chondral lesions, and extra-articular pathology. *Arthroscopy.* 2011 May;27(5):619-27. doi: 10.1016/j.arthro.2010.12.009.
22. Schmitz MR, Campbell SE, Fajardo RS, Kadrmaz WR. Identification of acetabular labral pathological changes in asymptomatic volunteers using optimized, noncontrast 1.5-T magnetic resonance imaging. *Am J Sports Med.* 2012 Jun;40(6):1337-41. doi: 10.1177/0363546512439991. Epub 2012 Mar 15.
23. Register B, Pennock AT, Ho CP, Strickland CD, Lawand A, Philippon MJ. Prevalence of abnormal hip findings in asymptomatic participants: a prospective, blinded study. *Am J Sports Med.* 2012 Dec;40(12):2720-4. doi: 10.1177/0363546512462124. Epub 2012 Oct 25.
24. Omoumi P, Thiery C, Michoux N, Malghem J, Lecouvet FE, Vande Berg BC. Anatomic features associated with femoroacetabular impingement are equally common in hips of old and young asymptomatic individuals without CT signs of osteoarthritis.
25. Wright JG, Swiontkowski ME, Heckman JD. Introducing levels of evidence to the journal. *J Bone Joint Surg Am.* 2003 Jan;85-A(1):1-3.
26. Clohisy JC, Baca G, Beaulé PE, et al. Descriptive epidemiology of femoroacetabular impingement: a North American cohort of patients undergoing surgery. *Am J Sports Med.* 2013 Jun;41(6):1348-56. doi: 10.1177/0363546513488861. Epub 2013 May 13.



27. Burnett RS, Della Rocca GJ, Prather H, Curry M, Maloney WJ, Clohisy JC. Clinical presentation of patients with tears of the acetabular labrum. *J Bone Joint Surg Am.* 2006 Jul;88(7):1448-57.
28. Nepple JJ, Riggs CN, Ross JR, Clohisy JC. Clinical presentation and disease characteristics of femoroacetabular impingement are sex-dependent. *J Bone Joint Surg Am.* 2014 Oct 15;96(20):1683-9. doi: 10.2106/JBJS.M.01320.
29. Lindner D, El Bitar YF, Jackson TJ, Sadik AY, Stake CE, Domb BG. Sex-Based Differences in the Clinical Presentation of Patients With Symptomatic Hip Labral Tears. *Am J Sports Med.* 2014 Jun;42(6):1365-9. doi: 10.1177/0363546514532226. Epub 2014 Apr 30.
30. Saadat E, Martin SD, Thornhill TS, Brownlee SA, Losina E, Katz JN. Factors Associated With the Failure of Surgical Treatment for Femoroacetabular Impingement: Review of the Literature. *Am J Sports Med.* 2014 Jun;42(6):1487-95. doi: 10.1177/0363546513500766. Epub 2013 Aug 30.
31. Skendzel JG, Philippon MJ, Briggs KK, Goljan P. The effect of joint space on midterm outcomes after arthroscopic hip surgery for femoroacetabular impingement. *Am J Sports Med.* 2014 May;42(5):1127-33. doi: 10.1177/0363546514526357. Epub 2014 Mar 7.
32. McCormick F, Nwachukwu BU, Alpaugh K, Martin SD. Predictors of hip arthroscopy outcomes for labral tears at minimum 2-year follow-up: the influence of age and arthritis. *Arthroscopy.* 2012 Oct;28(10):1359-64. doi: 10.1016/j.arthro.2012.04.059. Epub 2012 Aug 17.
33. Duc SR, Hodler J, Schmid MR, Zanetti M, Mengiardi B, Dora C, Pfirrmann CW. Prospective evaluation of two different injection techniques for MR arthrography of the hip. *Eur Radiol.* 2006 Feb;16(2):473-8. Epub 2005 Aug 16.
34. Giaconci JC, Link TM, Vail TP, Fisher Z, Hong R, Singh R, Steinbach LS. Morbidity of direct MR arthrography. *AJR Am J Roentgenol.* 2011 Apr;196(4):868-74. doi: 10.2214/AJR.10.5145.
35. Saupe N, Zanetti M, Pfirrmann CW, Wels T, Schwenke C, Hodler J. Pain and other side effects after MR arthrography: prospective evaluation in 1085 patients. *Radiology.* 2009 Mar;250(3):830-8. doi: 10.1148/radiol.2503080276. Epub 2009 Jan 21.
36. de Sa D, Cargnelli S, Catapano M, Bedi A, Simunovic N, Burrow S, Ayeni OR. Femoroacetabular Impingement in Skeletally Immature Patients: A Systematic Review Examining Indications, Outcomes, and Complications of Open and Arthroscopic Treatment. *Arthroscopy.* 2015 Feb;31(2):373-84. doi: 10.1016/j.arthro.2014.07.030. Epub 2014 Sep 26.